

Effectiveness of Scapular Proprioceptive Neuromuscular Facilitation with Maitland Glenohumeral Mobilization in Adhesive Capsulitis

Vishwa S¹, Divya N², Senthil kumar S³

¹Post Graduate, ³Associate Professor, Saveetha College of Physiotherapy, Saveetha Institute of Medical and Technical Sciences, Chennai, Tamilnadu, India, ²Assistant Professor, Faculty of Physiotherapy, MAHER, Chennai, India.

How to cite this article: Vishwa S, Divya N, Senthil kumar S. Effectiveness of Scapular Proprioceptive Neuromuscular Facilitation with Maitland Glenohumeral Mobilization in Adhesive Capsulitis. Indian Journal of Physiotherapy and Occupational Therapy / Volume 18 Special Issue 2024;

Abstract

Background: Adhesive capsulitis, an idiopathic condition that can cause severe disability, is characterized by fibrosis, a reduced glenoid capsule volume, and increasing pain with loss of range of motion (ROM) in the shoulder joint. In this study the efficiency of scapular Proprioceptive Neuromuscular Facilitation (PNF) with Maitland glenohumeral mobilization in adhesive capsulitis patients.

Purpose: This study was to evaluate the effectiveness of scapular Proprioceptive Neuromuscular Facilitation (PNF) mobilization with Maitland glenohumeral mobilization and) in subjects with adhesive capsulitis.

Methodology: Subjects were selected from out patient department of Saveetha Medical College and Hospital among 15 subjects following inclusion and exclusion criteria. Quasi-experimental study design, Convenient sampling is the sampling method. Range of motion and the numerical pain rating scale (NPRS) two outcome measures. Both the universal goniometer for ROM and the numerical pain rating scale (NPRS), which were used as outcome measures for adhesive capsulitis, were measured before and after the 16th therapy session. For four weeks, the treatment consisted of four-week sessions.

Conclusion: As a result of the findings, it was concluded that Scapular Proprioceptive Neuromuscular Facilitation with Maitland Glenohumeral Mobilization was effective in improving the Range of motion and reducing pain in Adhesive capsulitis.

Keywords: Adhesive capsulitis, Maitland glenohumeral mobilization, scapular Proprioceptive Neuromuscular Facilitation (PNF) mobilization, Numerical pain rating scale(NPRS), Range of motion(ROM).

Introduction

Adhesive capsulitis, often known as frozen shoulder, is a disorder characterised by shoulder stiffness, pain, and reduced range of motion. It occurs when the tissues around the shoulder joint become thick, tight, and annoyed, causing adhesions or scar

tissue to form. Although the specific aetiology of adhesive capsulitis is unknown, many variables can raise the likelihood of having the disorder. Adhesive capsulitis is more common in adults aged 40 to 60, and women are more likely than males to acquire it. is a disorder that makes daily tasks difficult by restricting

Corresponding Author: Vishwa .S, Post Graduate, Saveetha College of Physiotherapy, Saveetha Institute of Medical and Technical Sciences, Chennai, India.

E-mail: abbevishwa@gmail.com

shoulder joint flexibility. In 1872, Duplay coined the term “peri-arthritis scapula-humerae” to characterise the illness. However, Codman referred to it as frozen shoulder in 1934, highlighting how shoulder stiffness and pain could arise independently of external stimulation. Neviasser suggested the term “adhesive capsulitis” to designate a glenohumeral capsule ailment. The most typical cause of shoulder pain in middle-aged and older persons is adhesive capsulitis. Adhesive capsulitis is thought to be more common in females and the non-dominant hand, while the exact aetiology is unknown. It is more prevalent in those between the ages of 40 and 70 and is also considered to affect 2-3% of the general population. Primary and secondary adhesive capsulitis are the two basic types. The signs of primary or idiopathic adhesive capsulitis include a gradual onset of pain and stiffness at the gleno-humeral joint. The cause of this condition is unknown. Secondary adhesive capsulitis is known to be influenced by a number of risk factors. prior shoulder surgery or injury: Those who have undergone shoulder surgery or sustained an injury, such as a rotator cuff tear, are more likely to experience adhesive capsulitis¹. Frozen shoulder is more common in those with diseases like diabetes, thyroid problems, cardiovascular problems, and Parkinson’s disease. Stage of “freezing”: Movement is restricted and the shoulder eventually becomes uncomfortable. Even weeks to even months may pass during this phase. It becomes challenging to carry out daily duties during the frozen period, even though the discomfort may subside. Four to six months may pass during this stage. The range of motion gradually increases and the restriction on shoulder mobility lessens during the thawing period. This phase may endure for a few months to several years.

The origins of a frozen shoulder are poorly understood, and they frequently occur for unknown reasons. The aetiology of frozen shoulder may be brought on by chronic inflammation in musculotendinous or synovial tissue, such as the rotator cuff, biceps tendon, or joint capsule. As the frozen shoulder progresses, the capsule that surrounds the shoulder joint shrinks, making shoulder movements uncomfortable. According to some sources, spontaneous recovery typically occurs two years after the sickness initially appears, while according to other sources, long-term limits

are common without spontaneous recovery². That adhesive capsulitis is a self-limiting ailment that resolves in one to three years is common. However, a number of studies have shown that 20% to 50% of patients may go on to have ongoing issues³.

This condition develops gradually and causes pain over the deltoid insertion, sleep deprivation, painful incomplete elevation, painful external rotation, active and passive movement restriction, normal radiograph, and excruciating pain, but all patients are still able to go about their daily lives. With the possible exception of possible presence of osteopenia or calcific tendinitis in radiographs of the glenohumeral joint are largely normal in patients with frozen shoulders, which is characterised by functional restriction of both active and passive shoulder mobility^{4,6,7}.

When a patient arrives with shoulder pain and decreased mobility (adhesive capsulitis), clinicians should check for abnormalities in the musculotendinous structures surrounding the shoulder complex and the capsuloligamentous complex. A major finding that can be used to inform treatment strategy is the loss of passive motion in several planes, primarily external rotation with the arm at the side and in various degrees of shoulder abduction. (Recommendation supported by theoretical and fundamental data⁵).

Scapular Proprioceptive neuromuscular facilitation(PNF) mobilizing: Begin by having the patient seated with their arm hanging relaxed at their side and their scapula in a neutral position. Place one hand on the patient’s scapula and the other hand on their humerus. Begin by gently rocking the scapula towards the midline of the body, while applying a slight downward pressure with the hand on the humerus. At the end of the range of motion, pause and apply a gentle stretch by gently pushing the scapula away from the midline. Return the scapula to the starting position and repeat the process for the desired number of repetitions. Progressively increase the range of motion and pressure applied as the patient’s comfort level allows^{14,15}.

Maitland glenohumeral mobilization: Maitland glenohumeral mobilization is a type of manual therapy used to treat shoulder and upper extremity

joint pain. This technique involves the use of gentle and specific manual pressure to mobilize the shoulder joint and surrounding soft tissue. The goal is to improve range of motion, reduce pain, and improve soft tissue extensibility. Start with the patient in a seated or lying position and position the patient's arm in a comfortable position. Provide a gentle pressure to the shoulder joint, using your fingers or thumb to press and move the joint in a circular motion. Move the shoulder joint in a variety of directions and angles, including anterior, posterior, medial, and lateral. Use your other hand to provide resistance to the shoulder joint in order to increase the mobilization effect. Gradually increase the pressure and range of motion of the shoulder joint, paying special attention to the patient's comfort level and any signs of pain. After the desired range of motion has been achieved, perform light stretches to further increase the mobility of the shoulder joint. Finally, apply a light massage to the affected area in order to increase circulation and relieve stress.

Aim

The aim of this study was to evaluate the effectiveness of Maitland glenohumeral mobilization and scapular Proprioceptive Neuromuscular Facilitation (PNF) in subjects with adhesive capsulitis.

Materials and Methodology

Quasi-Experimental Study: Assessing the Efficacy of Intervention for Adhesive Capsulitis at Saveetha College and Hospital. This study aimed to investigate the effectiveness of a particular intervention for adhesive capsulitis in a quasi-experimental design. The study was conducted at Saveetha College and Hospital and utilized a convenient sampling technique. The sample consisted of 15 individuals aged between 45 to 65 years, ensuring gender equality. Inclusion criteria required participants to have adhesive capsulitis in the freezing stage, be diagnosed with unilateral adhesive capsulitis, and have either primary or secondary origins. Participants with malignancy, skin allergies, infections, recent shoulder surgery, recent history of trauma on the affected side, and shoulder pathologies other than adhesive capsulitis were excluded from the study. The study was conducted from June 2022 to November 2022.

Inclusion criteria:

- Age group 45 to 65 years
- Both gender male and female
- Freezing stage of adhesive capsulitis
- Unilateral adhesive capsulitis

Exclusion criteria:

- Osteomyelitis
- Recent history of shoulder surgery
- Malignancy
- Metabolic bone disease
- Skin allergy

Outcome Measures

The study used NPRS (numerical pain rating scale) and (ROM) Range of motion. NPRS measures pain severity and ROM measures shoulder movement. These measures guide treatment regimens for adhesive capsulitis.

Procedure

This quasi-experimental study was conducted at the Physiotherapy Outpatient Department of Saveetha Medical College and Hospital (SIMATS). Fifteen subjects with unilateral adhesive capsulitis were selected based on the inclusion and exclusion criteria, and their consent forms were obtained prior to the study. The study aimed to assess the effectiveness of Scapular Proprioceptive Neuromuscular Facilitation (PNF) mobilization combined with Glenohumeral Maitland mobilization as an intervention. Before the intervention, baseline assessments of the Numerical Pain Rating Scale (NPRS) score and the range of motion (ROM) of the affected shoulder joint were recorded for all participants. The intervention consisted of Scapular PNF mobilization with Glenohumeral Maitland mobilization, which was administered four times a week for four weeks. After completing the four-week intervention, post-test measurements of the affected shoulder's ROM and NPRS score were collected and analysed. The paired t-test was utilized to compare the mean differences between the pre and post-test values of both the ROM and NPRS score.

DATA ANALYSIS

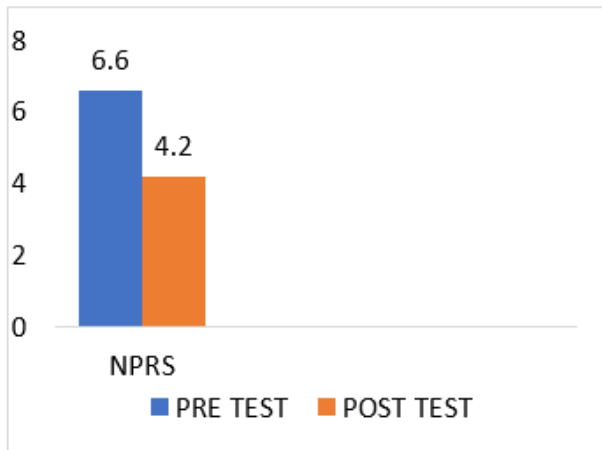


Fig 1: NPRS paired T - Test

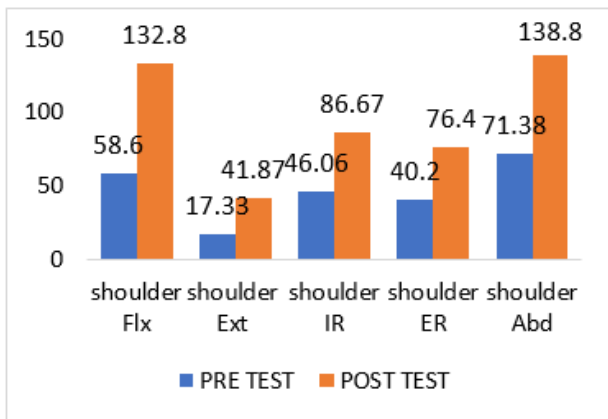


Fig 2: ROM paired T - Test

Result

The study presents fifteen participant. A single numerical pain rating scale (NPRS) and range of motion (ROM) were assigned at random to 15 individuals. A statically significant difference between pre and post was found after statistical examination of the qualitative data. The post-test was significantly more than the pre-test, with a p value of 0.0001 for the post-test numerical pain rating scale (NPRS) mean value of 6.60 and pre-test values of 4.20.

The post-test mean values on shoulder flexion, extension, abduction, internal rotation, and external rotation were 132.80, 41.87, 138.73, 86.67, and 76.40, respectively, while the pre-test mean values were 58.60, 17.33, 71.35, 46.0, and 40.20. This indicates that the post-test values were significantly higher than the pre-test values.

Discussion

This study evaluated the significance of combination of PNF and Maitland mobilization of shoulder joint causing the reduction of pain and increase in range of motion.in patients having adhesive capsulitis and scapular dyskinesis. Shimora and Kasai found a reduction in response time and improvement in range of motion due to increase in excitability. When Do Moon (2015) et al. compared the Maitland and Kaltenborn mobilization techniques, they discovered significant differences in pain and the range of motion of both internal and external shoulder rotation before and after the interventions, but not when the groups were compared for outcome measures ¹⁸.

AnnemeVan de Velde et al (2011 Mar-Apr) ¹⁹. The treatment were 12-week scapular training regimen significantly increased the isokinetic scapular muscle strength in healthy adolescent swimmers, and Merolla et al. reported that volleyball players with scapular dyskinesis experienced an increase in glenohumeral external rotator strength following a 6-month training regimen.

Merolla et al , found an increase in strength of glenohumeral external rotators with a 6 months training program in volleyball players having scapular dyskinesis Scapular external rotators plays an important role in overhead activities. Hence these studies has shown that there is a significant increase in functional outcome, strength and patient satisfaction with incorporation of scapular approach. ^{16,17}

In contrast to other research, which have used PNF scapular mobilization and Maitland Glenohumeral Mobilization separately to treat adhesive capsulitis, the two therapies were combined in this study, and the results were also positive.

Conclusion

The study aimed to determine whether Scapular PNF mobilization combined with Glenohumeral Maitland mobilization could be an effective treatment for individuals suffering from unilateral adhesive capsulitis. The findings from this study may contribute valuable insights into non-invasive physiotherapy interventions for adhesive capsulitis and could guide future treatment approaches for

improving patients' shoulder joint mobility and reducing pain. However, given the study's quasi-experimental design and limited sample size, further research with larger and more diverse populations is warranted to validate and generalize the results.

Ethical clearance: Approved by Institutional Scientific Review Board

Funding: Self

Conflict of Interest: Nil

References

- Nakandala P, Nanayakkara I, Wadugodapitiya S, Gawarammana I. The efficacy of physiotherapy interventions in the treatment of adhesive capsulitis: A systematic review. *Journal of back and musculoskeletal rehabilitation*. 2021 Jan 1;34(2):195-205.
- Çelik D, Kaya Mutlu E. Does adding mobilization to stretching improve outcomes for people with frozen shoulder? A randomized controlled clinical trial. *Clinical rehabilitation*. 2016 Aug;30(8):786-94.
- Neviasser JS. Adhesive capsulitis of the shoulder: a study of the pathological findings in periarthrosis of the shoulder. *JBJS*. 1945 Apr 1;27(2):211-22.
- Abrassart S, Kolo F, Piotton S, Chiu JC, Stirling P, Hoffmeyer P, Lädermann A. 'Frozen shoulder' is ill-defined. How can it be described better?. *EFORT open reviews*. 2020 May 1;5(5):273-9.
- Kelley MJ, Shaffer MA, Kuhn JE, Michener LA, Seitz AL, Uhl TL, Godges JJ, McClure PW, Altman RD, Davenport T, Davies GJ. Shoulder pain and mobility deficits: adhesive capsulitis: clinical practice guidelines linked to the international classification of functioning, disability, and health from the Orthopaedic Section of the American Physical Therapy Association. *Journal of orthopaedic & sports physical therapy*. 2013 May;43(5):A1-31.
- Bunker T. Time for a new name for frozen shoulder – contracture of the shoulder. *Shoulder & Elbow*. 2009 Jan;1(1):4-9
- Zuckerman JD, Rokito A. Frozen shoulder: a consensus definition. *Journal of shoulder and elbow surgery*. 2011 Mar 1;20(2):322-5.
- Mao CY, Jaw WC, Cheng HC. Frozen shoulder: correlation between the response to physical therapy and follow-up shoulder arthrography. *Archives of physical medicine and rehabilitation*. 1997 Aug 1;78(8):857-9.
- Alsubheen SA, Nazari G, Bobos P, MacDermid JC, Overend TJ, Faber K. Effectiveness of nonsurgical interventions for managing adhesive capsulitis in patients with diabetes: a systematic review. *Arch Phys Med Rehabil* 2019;100:350-365.
- Noten S, Meeus M, Stassijns G, Van Glabbeek F, Verborgt O, Struyf F. Efficacy of different types of mobilization techniques in patients with primary adhesive capsulitis of the shoulder: a systematic review. *Archives of physical medicine and rehabilitation*. 2016 May 1;97(5):815-25.
- Tasto JP, Elias DW. Adhesive capsulitis. *Sports medicine and arthroscopy review*. 2007 Dec 1;15(4):216-21.
- Joshi YS, Shridhar S, Jayaram M, Sharath UR. A Comparative Study on the Effect of Scapular Proprioceptive Neuromuscular Facilitation and Maitland Glenohumeral Mobilization Versus Scapular Mobilization and Maitland Glenohumeral Mobilization in Adhesive Capsulitis. *International Journal of Health Sciences and Research* Nov. 2020 Nov;10(11):135-43.
- Bhawna¹ NK, Kundu ZS. Prevalence of shoulder pain among adults in Northern India. *Asian Journal of Health and Medical Research (AJHMR)* Volume. 2016 Jun 2;2:18-22.
- Balcı NC, Yuruk ZO, Zeybek A, Gulsen M, Tekindal MA. Acute effect of scapular proprioceptive neuromuscular facilitation (PNF) techniques and classic exercises in adhesive capsulitis: a randomized controlled trial. *Journal of physical therapy science*. 2016;28(4):1219-27.
- Joshi YS, Shridhar S, Jayaram M, Sharath UR. A Comparative Study on the Effect of Scapular Proprioceptive Neuromuscular Facilitation and Maitland Glenohumeral Mobilization Versus Scapular Mobilization and Maitland Glenohumeral Mobilization in Adhesive Capsulitis. *International Journal of Health Sciences and Research* Nov. 2020 Nov;10(11):135-43.
- Van de Velde A, De Mey K, Maenhout A, Calders P, Cools AM. Scapular-muscle performance: two training programs in adolescent swimmers. *Journal of athletic training*. 2011 Mar 1;46(2):160-7.
- Merolla G, De Santis E, Campi F, Paladini P, Porcellini G. Supraspinatus and infraspinatus weakness in overhead athletes with scapular dyskinesis: strength assessment before and after restoration of scapular musculature balance. *Musculoskeletal surgery*. 2010 Dec;94:119-25.
- Do Moon G, Lim JY, Da YK, Kim TH. Comparison of Maitland and Kaltenborn mobilization techniques for improving shoulder pain and range of motion in frozen shoulders. *Journal of physical therapy science*. 2015;27(5):1391-5.
- Van de Velde A, De Mey K, Maenhout A, Calders P, Cools AM. Scapular-muscle performance: two training programs in adolescent swimmers. *Journal of athletic training*. 2011 Mar 1;46(2):160-7.