

# Effectiveness of Deep Brain Stimulation in Parkinsonism

Ajaydeep Singh<sup>1</sup>, Arvinpreet Kour<sup>2</sup>

<sup>1</sup>Assistant Professor, Department of Neurosurgery, <sup>2</sup>Assistant Professor, Department of Anaesthesia, Maharishi Markandeshwar Institute of Medical Science and Research, Mullana, Haryana, India

## Abstract

**Introduction:** Deep brain stimulation (DBS) is a neurosurgical procedure indicated for patients with advanced Parkinson's disease (PD). This study aimed to investigate the relative efficacy and safety of DBS when medical therapy is ineffective in advanced PD.

**Material and Method:** 50 patients whom were on medical treatment for long and started to have side effects of the drugs were the part of the study to find the improvement in the status in terms of tremors, dyskinesia and rigidity.

**Results:** Preoperatively and postoperatively comparison in the improvement was done which revealed, improvement was 75%, 61.5% and 58 % respectively in tremors, rigidity and dyskinesia. There was statically significantly improvement rigidity, tremor and the dyskinesia, the patients needed smaller doses of the medications and showed less signs of distress.

**Conclusion:** Our results clearly suggested that with Deep Brain Stimulation patients showed significant improvement with decreased dose of medication.

**Keywords:** DBS; Parkinsonism rigidity, dyskinesia and tremors, response of DBS on STN.

## Introduction

Parkinsonism is the detected in early 19<sup>th</sup> century, In the 1970's it became evident that long term levodopa treatment eventually could have disabling complications such as levodopa induced dyskinesias<sup>1</sup>. Hence, there was a need to find an alternative method to ablative surgical method, without irreversible side-effects. This resulted in the reappearance of DBS in the treatment of movement disorders. The pioneering work started in 1987 and was led by Alim-Louis Benabid and Pierre Pollak<sup>2</sup>. Deep brain stimulation (DBS) for Parkinson's disease, started

in 1987 when two group<sup>2,3</sup> reported results of chronic thalamic stimulation for parkinsonian tremor with nearly all patients having significant tremor suppression. The aim of this study was to compare the clinical outcomes of advanced PD patients following bilateral STN DBS, Electrode was passed The final positioning of the electrode checked by impedance monitoring, depth recording, and elicitation of evoked potentials and stimulation of presumed target. Parkinson's disease (PD) is a progressive and debilitating neurodegenerative disorder that affects 0.1 - 0.2% of the population at any time and 1% of the population over 60 years old, with the prevalence increasing in an age-dependent manner, Clinically, it is characterised by motor (tremor, rigidity, and bradykinesia), autonomic (constipation and orthostatic), and neurocognitive impairment (depression or sleep disorders.).

---

## Corresponding Author:

**Arvinpreet Kour**

Asistant Professor, Department of Anaesthesia, Maharishi Markandeshwar Institute of Medical Science and Research, Mullana, Haryana, India

e-mail: preetarvin27@gmail.com

Contact No.: +917006135661

## Materials and Method

This treatment was carried out at the Neurosurgery department. 50 patients of Parkinsonism were studied.

Inclusion criteria were: a diagnosis of idiopathic Parkinson's disease, age 30-75 years, good levodopa response, severe drug induced dyskinesia, Exclusion criteria were patients with pacemaker; patients with significant depression, and psychotic symptoms. The final targets achieved MRI brain were finalised with MER. **Study design.** For calculating the coordinates, MRI of the brain in stereotactic format was performed, later applied the frame and then CT brain was performed. Well-established Cartesian (x, y, and

z) target coordinates, relative to the mid-commissural point were used for planning electrode placement by frame link by Brain lab software Figure 1. Stereotactic target coordinates were discerned from frame link software that merges the MRI of the patient's brain with a brain atlas using plain CT.[figure 2] Positioning of the electrodes in the brain and final position of the target is checked by electrode checked by impedance monitoring, depth recording, and elicitation of evoked potentials and stimulation of presumed target. [Figure 3 and 4 ].

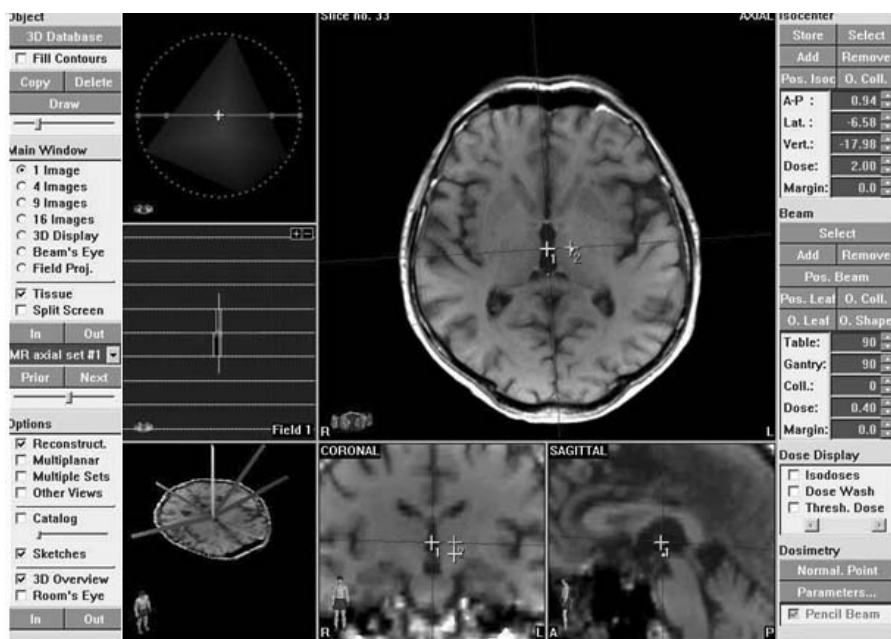


Figure 1. Localising the target and getting the coordinates with MRI brain.

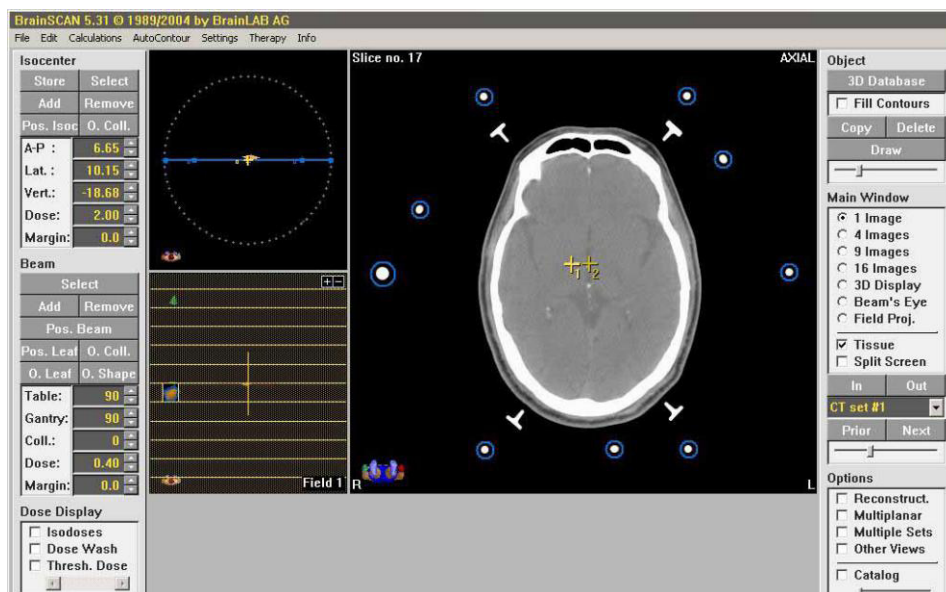
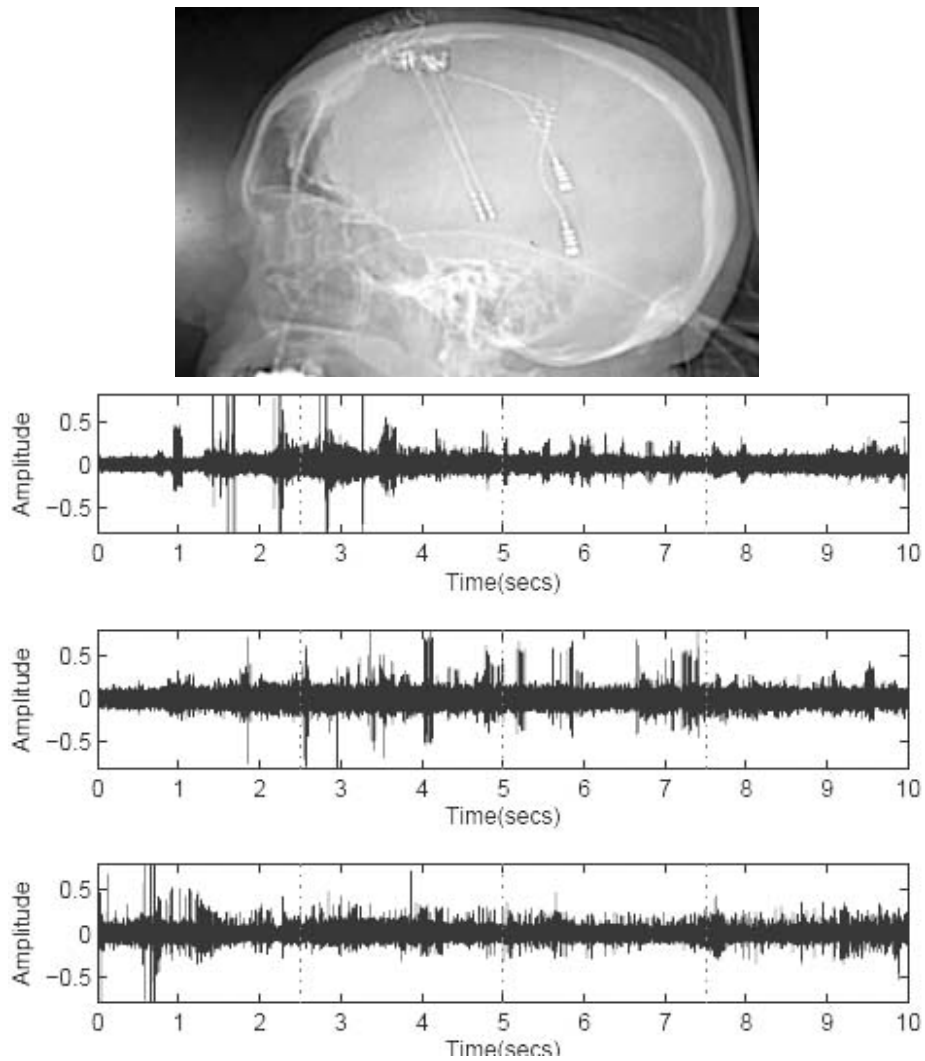
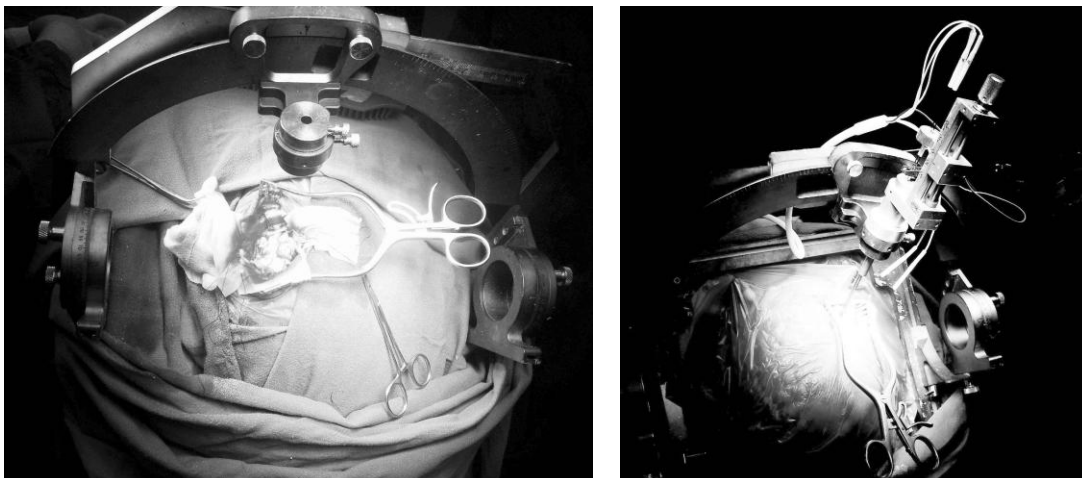


Figure 2 CT scan images used for merging in the frame link software



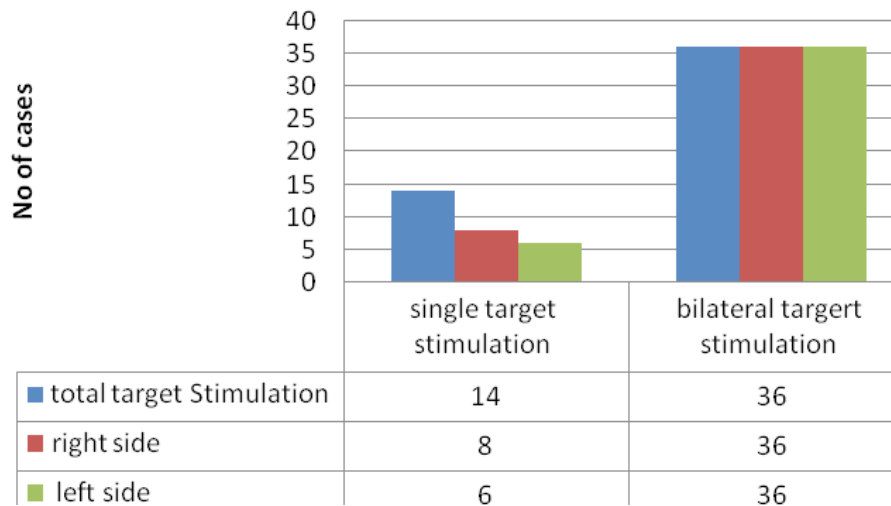
**Figure 3 & 4** Positioning of the electrodes in the brain and final position of the target is checked by electrode checked by impedance monitoring, depth recording, and elicitation of evoked potentials and stimulation of presumed target.

**STN stimulation:** Out of 50 patients in the 36 patient were bilaterally stimulated and 14 patients were unilaterally stimulated assessing the side of the disease. In total 86 targets were stimulated.



**Figure 5** Intraoperative electrodes placement

## STN stimulation



**Gender:** Out of 50 patients 10 (20%) were female and 40 (80%) patients were males. The frame used is fixed to the patient under local anaesthesia.




Figure 6 shows . Arc of the frame with phantom base and picture of the frame fitted to the patient

*Clinical rating scales.* The clinical improvements of the patients were studied preoperatively and postoperatively accordingly to the UPDRS score. The Unified Parkinson Disease Rating Scale (UPDRS) is designed to monitor Parkinson Disease disability and impairment<sup>3</sup>.

The Unified Parkinson Disease Rating Scale (UPDRS) is designed to monitor Parkinson Disease disability and impairment.

**It measured the following levels:**

0 = Absent.

1 = Slight and infrequently present.

2 = Mild in amplitude and persistent. Or moderate in amplitude, but only intermittently present.

3 = Moderate in amplitude and present most of the time.

4 = Marked in amplitude and present most of the time.

**The UPDRS consists of 4 different parts:**

**1. Mentation, Behavior and Mood**

1. Intellectual Impairment
2. Thought Disorder
3. Depression
4. Motivation/Initiative

**2. Activities of Daily Living (for both “on” and “off”)**

1. Speech
2. Salivation
3. Swallowing

4. Handwriting
5. Cutting food and handling utensils
6. Dressing
7. Hygiene
8. Turning in bed and adjusting bed clothes
9. Falling
10. Freezing when walking
11. Walking
12. Tremor
13. Sensory complaints related to parkinsonism

### 3. Motor Examination

1. Speech
2. Facial Expression
3. Tremor at rest
4. Action or Postural Tremor of hands
5. Rigidity
6. Finger Taps
7. Hand Movements
8. Rapid Movements of Hands
9. Leg Agility
10. Arising from Chair
11. Posture
12. Gait
13. Postural Stability
14. Body Bradykinesia and Hypokinesia

### 4. Complications of Therapy (In the past week)

#### 1. A. Dyskinesias

1. Duration: What proportion of the waking day are dyskinesias present?
2. Disability: How disabling are the dyskinesias?
3. Painful Dyskinesias: How painful are the dyskinesias?
4. Presence of Early Morning Dystonia

#### 2. B. Clinical Fluctuations

1. Are “off” periods predictable?
2. Are “off” periods unpredictable?

3. Do “off” periods come on suddenly, within a few seconds?
4. What proportion of the waking day is the patient “off” on average?

#### 3. C. Other Complications

1. Does the patient have anorexia, nausea, or vomiting?
2. Any sleep disturbances, such as insomnia or hyper somnolence?
3. Does the patient have symptomatic orthostasis?

**Complications:** Complications were classified into operation-related, hardware-related and stimulation-related.

#### Operation-related complications included:

1. Intracranial hemorrhages,
2. Neurological deficits,
3. Venous infarct,
4. Venous air embolism,
5. Seizures
6. Electrode malposition,
7. Pulmonary embolism.

#### Hardware-related complications included

1. Fracture of electrodes,
2. Electrode migration,
3. Infection,
4. Erosion.

#### Stimulation-related complications included

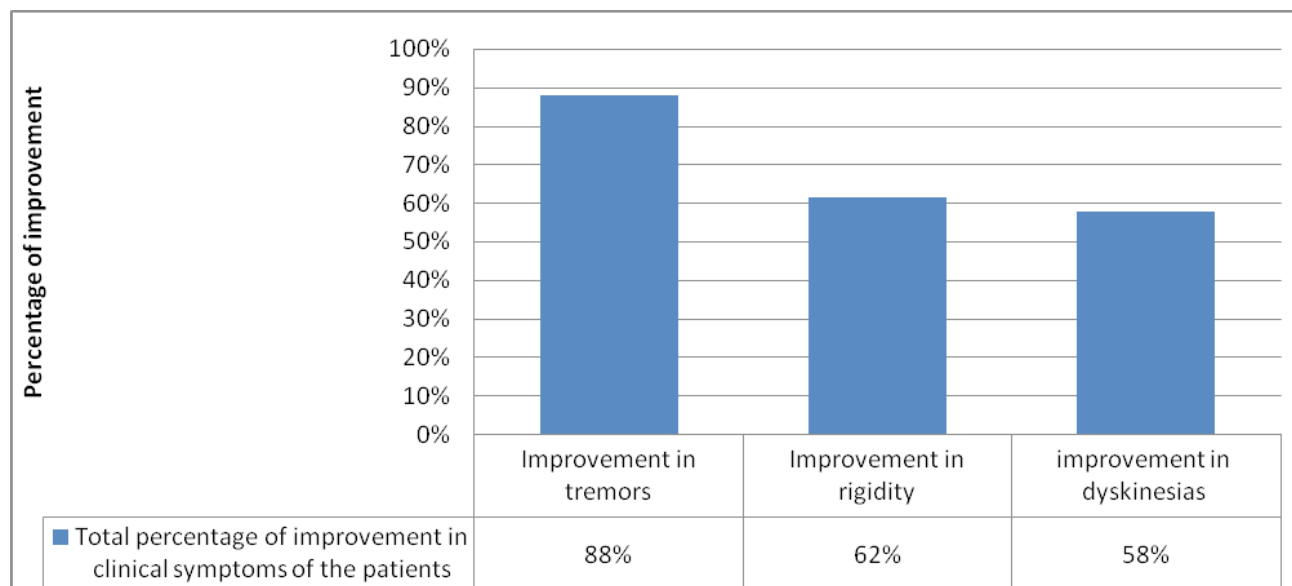
1. Sensorimotor conditions,
2. Psychiatric conditions,
3. Life-threatening conditions.

**Statistical significance:** Statistical analysis of the data was performed by using Statistical Package for the Social Sciences Version 20 SPSS version 20, Paired T Test, Wilcoxon signed rank test and by R software with KW Test, Mann Whitney and t-stat, To indicate statistical significance p value < 0.01 for paired t test and < 0.05 for Wilcoxon signed rank test, KW Test, Mann Whitney and t-stat was taken.

## Results

Comparisons of the results were done on the basis by grading the tremors, rigidity and dyskinesias with grade

of 0-4 on clinical examination pre and postoperatively. The score obtained was calculated was calculated in percentages and was correlated with scoring system and the outcome was measured.



Comparison of tremors in the patients preoperatively and postoperatively

## Discussion

The improvement in the clinical symptoms of the patients of DBS at subthalamic nucleus were studied in 50 patients, Overall the surgery was well tolerated, with the exception of three patient developed bleed {one thalamic bleed and 2 cortical }; the patient was managed with conservative treatment with medications and mannitol was given in one. The target of the subthalamic nuclei<sup>4-6</sup> were the closest to the final target, confirmed by microelectrode recording<sup>5, 7</sup>, as similarly reported, visual target as possibly more accurate<sup>7-10</sup> An accuracy of 84.76 % was achieved in localising the subthalamic nuclei, confirmed with microelectrode recording. Patients achieved the best results in Unified Parkinson’s Disease Rating Scalescores in both “on and off” state<sup>11</sup>. The improvement in rigidity, tremor and the dyskinesia due to subthalamic nuclei stimulation correlated well with the improvement of the other sensory and motor parkinsonian symptoms<sup>13</sup>. A trajectory of 50°-60°was used<sup>13</sup>, which correlated with the alignment of the subthalamicnuclei. The best results were achieved in the dorsolateral portion of the subthalamic nuclei<sup>14,15,16</sup>. The ventral portion of subthalamic nuclie which was

better visualised in the magnetic resonance imagingis associative areas and has connections with the limbic system<sup>17</sup>.

It is likely that there were several unavoidable errors in this study e.g positions of the electrodes while fusing magnetic resonance imaging/computed tomography, direct visualisation of subthalamic and inter-evaluator errors, and errors in plotting the electrodes in the brain atlas based on the fused images<sup>18,19</sup>. Secondly there are distortions in the magnetic resonance imaging which may lead the displacement of the targets<sup>18</sup>. Thirdly it is rare that all the borders of the subthalamic nuclei are not visualised with precision, Systematic reviews and meta-analyses of randomized controlled trials comparing DBS to the best medical therapy are limited. Perestelo-Pérez et al.<sup>20</sup> showed that DBS was superior to BMT for improving motor control, QoL, and medication doses in PD patients. Finally, the long-term outcome of the patients who underwent programming after subthalamic nuclei deep brain stimulation needs to be assessed. Hitti FL et al in their study of DBS for PD showed 10-year survival rate of 51%. Survey data suggest that while DBS does not halt disease progression in PD, it provides

durable symptomatic relief and allows many individuals to maintain ADLs over long-term follow-up greater than 10 years<sup>21</sup>.

### Conclusions

There has been Substantial improvement in the quality of life in the patients who had DBS with medical therapy, we found that tremors and rigidity had significant improvement the compliance was better and significantly decreasing medication costs. The only drawback in the developing country was that the expense of the procedure (10-15 lakh) makes the procedure unreachable to the middle class patients . The efficacy of DBS has been established.he efficacy of DBS has been established, yet the question remains as to whether DBS should be considered as a treatment option at an earlier stage than the current recommendations.

**Ethical Clearance:** Taken from Indraprastha Apollo Hospital Delhi ethical committee

**Source of Funding:** Self

**Conflict of Interest:** Nil

### References

- Schwartz, A., Rosenberg, G., Spencer, A., Barbeau, A., Mars, H. & Libman, I: The effects of levodopa therapy in patients with Parkinson's disease. I. Clinical response. *Can Med Assoc J*, (1972) 107, 973-6.
- Hassler, R., Riechert, T., Mundinger, F., Umbach, W. & Ganglberger, J.A: Physiological observations in stereotaxic operations in extrapyramidal motor disturbances. *Brain*, (1960) 83, 337-50.
- Poewe W. Clinical measures of progression in Parkinson's disease. *Mov Disord*. 2009;24(S2):S671-76.
- Priori A, Egidi M, Pesenti A, Rohr M, Rampini P, Locatelli M: Do intraoperative microrecordings improve subthalamic nucleus targeting in stereotactic neurosurgery for Parkinson's disease? *J Neurosurg Sci*. 2003 Mar;47(1):56-60.
- Pollo C, Meuli R, Maeder P, Vingerhoets F, Ghika J, Villemure JG: Subthalamic nucleus deep brain stimulation for Parkinson's disease: magnetic resonance imaging targeting using visible anatomical landmarks. *Stereotact Funct Neurosurg*. 2003;80(1-4):76-81.
- Hamid NA, Mitchell RD, Mocoft P, Westby GW, Milner J, Pall H: Targeting the subthalamic nucleus for deep brain stimulation: technical approach and fusion of pre- and postoperative MR images to define accuracy of lead placement. *J Neurol Neurosurg Psychiatry*. 2005 Mar; 76(3):409-14.
- Littlechild P, Varma TR, Eldridge PR, Fox S, Forster A, Fletcher N et al., Variability in position of the subthalamic nucleus targeted by magnetic resonance imaging and microelectrode recordings as compared to atlas co-ordinates. *Stereotact Funct Neurosurg*. 2003;80(1-4):82-7.
- Slavin KV, Thulborn KR, Wess C, Nersesyan H: Direct visualization of the human subthalamic nucleus with 3T MR imaging. *AJNR Am J Neuroradiol*. 2005 Jan;27(1):80-4.
- Patel NK, Khan S, Gill SS: Comparison of atlas- and magnetic-resonance-imaging-based stereotactic targeting of the subthalamic nucleus in the surgical treatment of Parkinson's disease. *Stereotact Funct Neurosurg*. 2008;86(3):153-61.
- Daniluk S, G Davies K, Ellias SA, Novak P, Nazzaro JM: Assessment of the variability in the anatomical position and size of the subthalamic nucleus among patients with advanced Parkinson's disease using magnetic resonance imaging. *Acta Neurochir (Wien)*. 2010 Feb;152(2):201-210
- Limousin P, Krack P, Pollak P, et al. Electrical stimulation of the subthalamic nucleus in advanced Parkinson's disease. *N Engl J Med* 1998; 339:1105-11
- Schaltenbrand G, Wahren W. Atlas for Stereotaxy of the Human Brain. Stuttgart, New York: Thieme; 1977.
- Starr PA, Christine CW, Theodosopoulos PV, Lindsey N, Byrd D, Mosley A, Marks WJ Jr: Implantation of deep brain stimulators into the subthalamic nucleus: technical approach and magnetic resonance imaging-verified lead locations. *J Neurosurg*. 2002 Aug;97(2):370-87.
- Slavin KV, Thulborn KR, Wess C, Nersesyan H: Direct visualization of the human subthalamic nucleus with 3T MR imaging. *AJNR Am J Neuroradiol*. 2005 Jan;27(1):80-4.
- Elyne Kahn, Pierre-Francois, Benoit Dawant, Laura Allen, Koa Chris, Charles P David, Konrad Peter: Deep Brain Stimulation in Early Stage Parkinson's Disease: Operative Experience from a Prospective,

- Randomized Clinical Trial: *J Neurol Neurosurg Psychiatry*. 2012 Feb; 83(2): 164–170.
16. Hamel W, Fietzek U, Morsnowski A, Schrader B, Herzog J, Weinert D et al., Deep brain
  17. Stimulation of the subthalamic nucleus in Parkinson's disease: evaluation of active electrode contacts. *J Neurol Neurosurg Psychiatry*. 2003 Aug; 74(8): 1036–1046.
  18. Lanotte MM, Rizzone M, Bergamasco B, Faccani G, Melcarne A, Lopiano L : Deep brain stimulation of the subthalamic nucleus: anatomical, neurophysiological, and outcome correlations with the effects of stimulation. *J Neurol Neurosurg Psychiatry* 2002;72:53–58
  19. Shin-Yuan Chen,Chao-Chin Lee, Sheng-Huang Lin, Yue-Long Hsin, Tien-Wen Lee, Pao-Sheng Yen, et al: Microelectrode recording can be a good adjunct in magnetic resonance image–directed subthalamic nucleus deep brain stimulation for parkinsonism. *Surgical Neurology Volume 65, Issue 3, March 2006, Pages 253–260.*
  20. Perestelo-Pérez L, Rivero-Santana A, Pérez-Ramos J, et al. *J Neurol*. Vol. 261. Heidelberg: Online] Springer Berlin; 2014. Deep brain stimulation in Parkinson's disease: meta-analysis of randomized controlled trials; pp. 2051–2060. [PubMed] [Google Scholar]
  21. Hitti FL, Ramayya AG, McShane BJ, Yang AI, Vaughan KA, Baltuch GH. Long-term outcomes following deep brain stimulation for Parkinson's disease. *J Neurosurg*. 2019 Jan 18:1-6. doi: 10.3171/2018.8.JNS182081.