

Comparative Anatomical Study of Kidney in adult Male Squirrel (*Sciurus anomalus*) and Mice (*Mus musculus*)

Mohammed H. Abed¹, Shakir M. Mirhish²

¹PhD. Student, ²Prof., Department of Anatomy and Histology, College of Veterinary Medicine, Baghdad University, Iraq

Abstract

The current study aimed to investigate the anatomical, morphological, morphometrical data of the kidney in two types of rodent, the squirrel and mice. A total number of 80 kidneys were obtaining from two species which include 40 specimens from squirrels and same number of specimens from mice.

Current study showed that the kidneys in two species lay in the abdominal cavity lying retroperitoneal against upper dorsal wall rear of abdominal cavity on either side of vertebral column.

The left kidney in squirrel was longer and thicker than right kidney while in mice was reversible and in both animal the left kidney more distant from the median plane than the right but the left kidney in squirrel was larger than right kidney the value.

Shape of kidneys in squirrel appeared semi bean like structure but in mice the shape was typical bean like structure, and in both animals the kidneys have smooth surface. Both kidneys of squirrel were by relatively solid texture in contrast with mice kidney.

The biometrical measurements of the kidney revealed that the mean weight in squirrel was significantly larger than that of mice. Whereas all micro measurements recorded showed a significant differences between squirrel and mice where the means in squirrel appeared higher than those of mice.

Renal artery which arises from abdominal aorta divided to the right branches, the right artery appeared shorter than the left artery, because the left kidney being more distant from the median plane than the right one. The renal artery in mice divided into 3 branches called anterior renal artery, intermediate renal artery and posterior renal artery but in squirrel divided to 2 branches anterior and posterior renal artery. in both animals the 2nd order of artery branches intermediate renal artery divided in mice in 4 interlober branches but in squirrel the interlober divided into 6 branches

Keywords: Anatomical of Kidney, adult male squirrel (*Sciurus anomalus*) , mice (*Mus musculus*)

Introduction

The urinary system of mammals consists of

the paired kidneys, ureters, urinary bladder, and urethra ⁽¹⁾. Urinary system that contributes to the maintenance of homeostasis by complex process that involves filtration, absorption and secretion .It's also regulates fluid and electrolyte balance of the body and the site of production of renin, a substance

Corresponding author :

Shakir M. Mirhish:

email: firmas_rashad@yahoo.com

that regulate blood pressure and erythropoietin that stimulate the production of erythrocyte. Additional functions include excretion of waste products from the processing of food, drugs, and harmful substances; and secretion of certain hormones and its function in osmoregulation to act as thermoregulation of body (2;3;4).

The kidney is a bean-shaped structure with a convex and a concave border. A recessed area on the concave border is the renal hilum, where the renal artery enters the kidney and the renal vein and ureter leave. The kidney is surrounded by tough fibrous tissue, the renal capsule, which is itself surrounded by perirenal fat, renal fascia, and pararenal fat (5;6).

Laboratory animals similar to rats and mice they have shorter generation interval and they yield quick return on low investment. Kidneys play an important role in maintaining homeostasis and more concentrated urine (7).

The physiological adaption of small rodents to arid conditions is achieved mainly through concentrating ability of their kidneys (8).

The conservation of water by the kidney is of crucial importance for the kangaroo rat, which does not drink and can obtain water only from catabolism while, other desert rodents obtain water from their diet (9).

Because of the rareness of studies that deals with the comparison between the urinary system of squirrel and mice, this study was conducted to investigate the morphological features and morphometric measurements of kidney in these two animals.

Materials and Methods

A total number of 80 kidneys were obtaining from two species of apparently adult healthy male rodent animals which include 40 specimens from squirrels (*Sciurus anomalus*) and same number of specimens

from mice (*Mus musculus*). All squirrels included in this study are obtained from local market (Alghazzel market) in Baghdad city and the mice were brought from (animal house in College Veterinary Medicine of Baghdad University).

The animals were weight alive by using digital electrical balance and the animals are euthanized by intramuscular injection of a mixture of ketamine and xylazine at dose ketamine 25 mg/kg of body weight and xylazine 10-12.5 mg/kg (10;11).

A vertical midline Incision was done from the xiphoid process down to the inguinal region under the skin, abdominal muscle to the abdominal cavity and the viscera were retracted and the kidneys were exposed, location, shape, color and boundaries and relationship of kidneys were recorded then the kidneys were released from their fat covering connective tissue and gently removed.

Gross anatomical measurements include the following parameters:

- a- Length of kidney / mm from cranial pole to caudal pole. By digital vernier
- b- Width of kidney / mm. digital vernier
- c- Thickness of kidney from middle /mm. digital vernier
- d- Volume of kidney/ml. using water displacement measured using the immersion method
- e- Weight of kidney / gm by electrical sensitive balance.
- f- Blood supply: by using resin

Resin injection procedure:

Catheter (hospital and homecare medical device co. /made in china) used for squirrel CH/FR: 6 but in mice CH/FR:4 was inserted aortic arch reaching

into the renal artery of fresh kidney and made knot it around the the tube with the vessel will restrict and avoid the slippage during perfusion act as valve after complet injection is close the knot. The resin was prepared after mixed (Powder and liquid 1 to 4), and it is consisted of 20% monomethyl-methacrylate powder and 80% polymethyl-methacrylate liquid and adding the suitable dyes (Red, blue and yellow ink or oil painting dyes). The mixture is taken in a separate syringe and connected to the tube. The resin is perfused with constant injection pressure to avoid blockage or rupture of small capillaries after that of inject the renal blood vessels by mixture of self-cure denture material set. To differentiate the blood vessels samples are incubated at room temperature for 48-72 hours for polymerization (Duracryl Plus Company / Czech Republic)

After that, the samples of cast were macerated by using (KOH) (12;13;14;15).

Statistical Analysis

Computer package (Sigma plot V12.0 / SYSTAT software) was used to conduct the histomorphometrical analysis. Data were presented as means \pm SE (standard error) and were analyzed using Duncan's test with significant level set on $P < 0.05$.

Results

Present study investigated anatomical, morphological, morphometrical data of the kidney comparing between two types of rodent species, one of them was called squirrel (*Sciurus anomalus*) and the second called mice (*mus musculus*).

Gross anatomical and morphometrical study revealed that the male squirrel (*sciurus anomalus*) mean body weight was significantly higher than mice (*mus musculus*) where they measured (200.29 \pm 20.2, 31.17 \pm 2.3gm.) respectively (Table 1).

Table 1: showing weight of both animals / grams

Animal	weight of body (g)	P-value
Squirrel	200.29 \pm 20.2	<0.0001
Mice	31.17 \pm 2.3	

Current study showed that the kidneys lay on the upper lumbar region in the abdominal cavity lying retroperitoneal against upper dorsal wall rear of abdominal cavity just above the waistline on either side of vertebral column (fig.1A,B).

In both animals male squirrel and mice the kidneys localization on each side of vertebral column asymmetrical in location, the right kidney is located more cranial than the left kidney and the right kidney

settle, nearest of median plane in squirrel and mice and the cranial pole of the right kidney covered partially by the right lobe of liver and made the renal impression caudally but the left kidney related with spleen and parietal layer of stomach, the descending colon, the body of the pancreas and jejunum, while the cranial extremity of both kidneys related with the adrenal gland with each one.

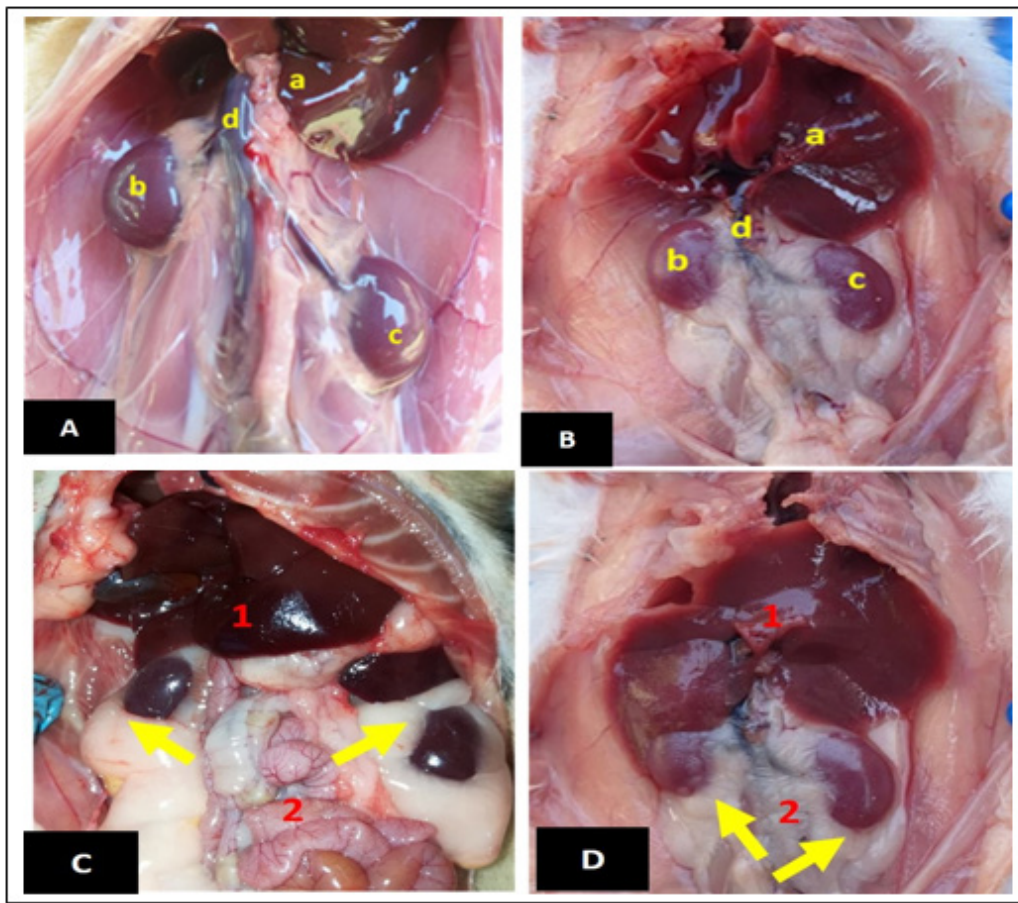


Figure: (1)

A: The location of squirrel kidney a. liver b. right kidney c. left kidney d. aorta and caudal venacava.

B: The location of mice kidney a.liver b.right kidney c.left kidney d.aorta and caudal venacava.

C: Adipose tissue surrounding kidney (yellow arrow) (liver 1) (intestine 2) in squirrel.

D: Adipose tissue surrounding kidney (yellow arrow) (liver 1) (intestine 2) in mice.

The left kidney in squirrel was longer and thicker than right kidney while in mice was reversible and in animals, the left kidney more distant from the median plane than the right but the left kidney in squirrel was larger than right kidney the value.

In mice (*mus musculus*), our study showed that the size of the right kidney slightly was larger than left kidney with non-significant differences.

Our study in squirrels showed there was a large amount of adipose tissue depositions completely surrounds of both kidney (fatty layer like cushion)

But in mice there was a little or light quantity of the adipose tissue which occupy the renal sinus and surrounded the renal vessels and origin of ureter (fig.1,c,d) respectively.

The study revealed that the kidneys surface of both animals male squirrel and mice don't have capsular vein. The study revealed the kidneys surface of both animals don't have capsular vein

Shape of kidneys in squirrel appeared semi bean like structure, but not highly typical (fig.2 A,B) but in mice the shape was typical bean like structure, clearer

margin and in both animals the kidneys have smooth surface without any lobulation or fissures. Both kidneys of squirrel was characterized by relatively solid in contrast with mice kidney in texture.

In both animals, the kidney appeared with rounded cranial and caudal pole, dorsal and ventral surface and had medial and lateral borders, the lateral border

was convex while, the medial border was concave, at the middle of medial border at deep concave region occupied by hilum, represent the site of entrance of renal artery and exist renal vein and ureter exit from the kidney. The study revealed that the color of kidneys were reddish-brown in both animal squirrel and mice.

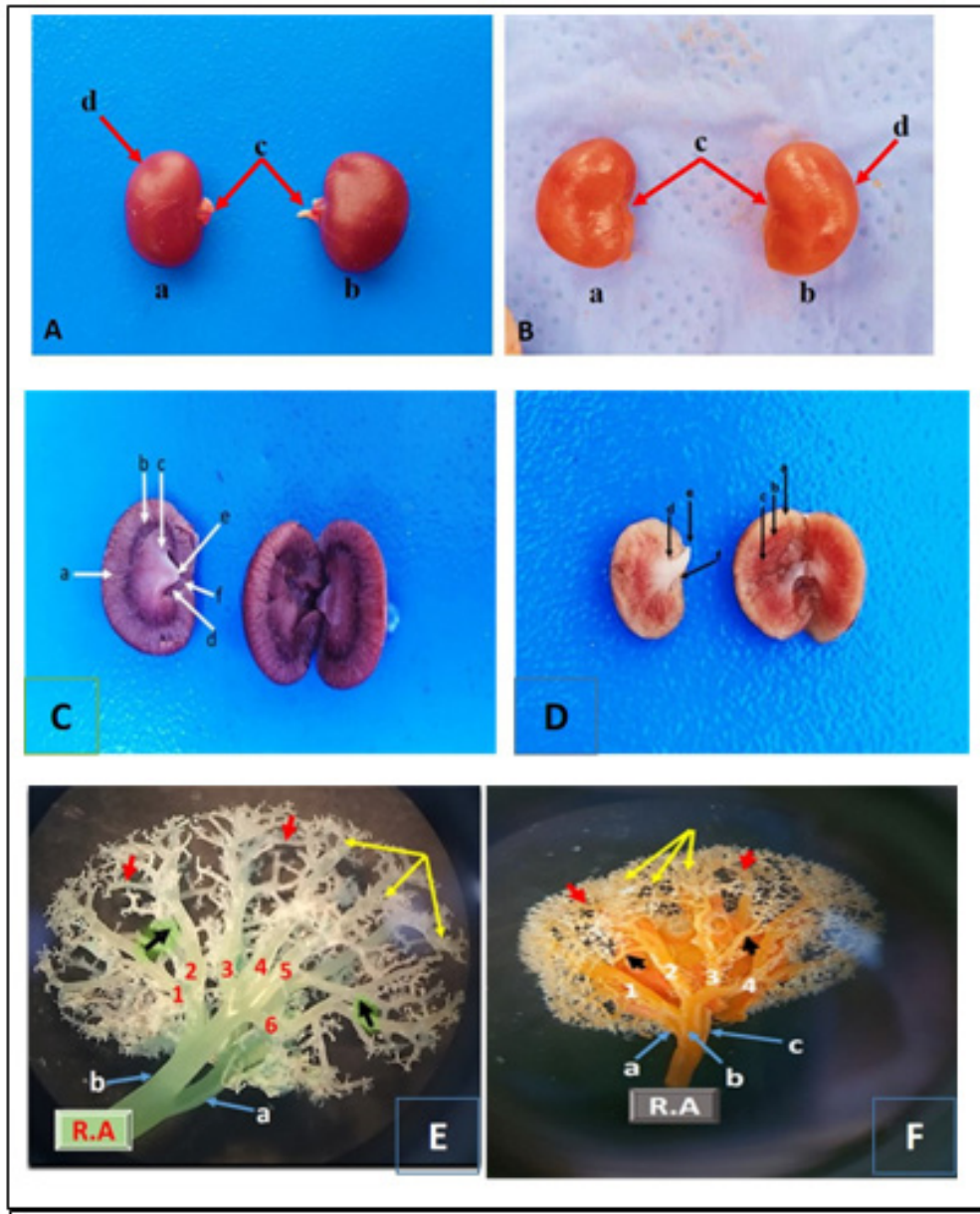


Fig.2 A: Squirrel kidney a.right kidney b.left kidney c.hillus of kidney d.renal capsule without capsular vein. **B:** E: Mice kidney a.right kidney b.left kidney c.hillus of kidney d.renal capsule without capsular vein.

C: Longitudinal section of male squirrel kidney
 a.renal cortex b.renal medulla (external zone) c.renal medulla (internal zone) d.renal sinus e.renal papillae f.renal pelvis.

D: Longitudinal section of male mice kidney
 a.renal cortex b.renal medulla (external zone) c.renal medulla (internal zone) d.renal sinus e.renal papillae f.renal pelvis.

E: dorsal view blood supply (corrosion cast) of squirrel kidney showing:

R.A-Renal artery a-Anterior renal artery
 b-Posterior renal artery 1,2,3,4,5,6-interlobar renal artery (black arrow)-interlobular renal artery(red arrow)-arcuate renal artery (yellow arrow)-vasa recta and cortical radiated arteries

F: Dorsal view blood supply (corrosion cast) of mice kidney showing:

R.A-Renal artery a-Anterior renal artery

b-Posterior renal artery 1, 2, 3, 4,-interlobar renal artery (black arrow)-interlobular renal artery(Red arrow)-arcuate renal artery (yellow arrow)-vasa recta and cortical radiated arteries.

Measurements

The biometrical measurements of the kidney revealed that the mean weight in squirrel (*Sciurus anomalus*) was significantly larger than that of mice (*mus musculus*) (1.25±0.03 gm., 0.49±0.02gm) respectively. Table (2) showed that there was no significant difference in all micromorphometric measurements between right and left kidneys in squirrel as well as in mice.

The measurements recorded in table (2) showed a significant differences between squirrel and mice where the means in squirrel appeared higher than those of mice.

Table-2: Showing the anatomical measurements in squirrel and mice

Groups	Weight of kidney (gm)	Length of right kidney (mm)	Length of left kidney (mm)	Width of right kidney dorso-ventrally (mm)	Width of left kidney dorso-ventrally (mm)	Thickness from middle of right kidney (mm)	Thickness from middle of left kidney (mm)	Thickness of cranial pole of right kidney (mm)	Thickness of cranial pole of left kidney (mm)	Thickness of caudal pole of right kidney (mm)	Thickness of caudal pole of left kidney (mm)	Volume of kidney in water(ml)
Squirrel	1.25±0.03 *	17.16±0.2 *	17.48±0.3 *	10.24±0.7 *	10.52±0.3 *	8.18±0.4 *	8.28±0.8 *	7.58±0.9 *	7.81±0.6 *	6.63±0.2 *	6.79±0.3 *	4.37±0.5 *
Mice	0.49±0.02	10.42±0.9	10.30±0.3	6.29±0.6	6.36±0.6	5.74±0.3	5.73±0.3	4.50±0.2	4.40±0.2	3.94±0.2	3.68±0.1	3.39±0.06

The index of cortex to medulla in squirrel was (1:2.8) while in mice was (1:1.5). Longitudinal section revealed outer most dark brown granulated area referred to cortex. The medulla consists of two distinctive region the outer dark and inner paler medulla with shallow striation (fig.2,C,D).

Blood supply

The blood supply arises from abdominal aorta where each kidney was supplied usually by a single artery, called. Renal artery divided to the right side (right artery) and to the left side (left artery), the right artery appeared shorter than the left artery, because

the left kidney being more distant from the median plane than the right one (Fig.1A,B). Renal artery enter the kidney at hilum and branched. The renal artery in mice divided into 3 branches called anterior renal artery, intermediate renal artery and posterior renal artery but in squirrel the corrosion cast revealed that the renal artery divided to 2 branches anterior and posterior renal artery. in both animals the 2nd order of artery branches intermediate renal artery divided in mice in 4 inerlober branches but in squirrel the interlober divided into 6 branches after that in both animals the interlober divided into interlobular, then to arcuate and cortical radiated artery and ends into

afferent, efferent and glomeruli.(Fig.2 E,F)

Discussion

It has been recorded that any species of animals survive in different environments need physiological and anatomical features that arrange the body water. This could be done through the production and concentration of urine, rendering to the structure of the kidneys and urinary tract, which are developed as a response to several environmental aspects involving morphological differences ⁽¹⁶⁾.

The present study was revealed that there was a differences in location and size of kidneys between the squirrel and mice which belong to the size of body, age, family and climate of living ,these findings come in agreement with ⁽¹⁷⁾ in Guinea pig and ⁽¹⁸⁾ in jerboa (*Jaculus jaculus*) who mentions the kidney located retroperitoneal in caudal portion of the upper abdomen cavity on each side of spinal cord under the sub-lumbar region situated in the posterior part of the abdomen on each side of the vertebral column. In addition the present observations are contrast with that observation of, ⁽¹⁹⁾ in all studied mammals and ⁽²⁰⁾ in desert rodents.

The left kidney was in squirrel longer and thicker than right kidney in mice was reversible and in both animal the left kidney more distant from the median plane than the right but the left kidney in squirrel was larger than right kidney, the value in this study were also similar to those results of ⁽¹⁸⁾ in jerboa and ⁽²¹⁾ in rabbit who registered the left kidney weight and dimensions more than right kidney but unlike result in albino rat⁽²²⁾, house mice⁽⁶⁾, desert rodents ^(20,23), guinea pig⁽¹⁷⁾, and rabbit⁽²⁴⁾.

Our study in squirrels revealed there was a large amount of adipose tissue depositions completely surrounds of both kidney (fatty layer like cushion) act as insulator a protective layer protect against distorting pressure from adjacent organs giving

additional support for kidneys capsule and after this layer adhesion connective tissue capsule But in mice little or light quantity of the adipose tissue and the adipose tissue which occupy the renal sinus and surrounded the renal vessels and origin of ureter (fig.3,a,b) respectively these results is agreement with ⁽¹⁸⁾ in jerboa (*Jaculus jaculus*), albino rat⁽²²⁾, African gaint rat and wistar rat⁽⁴⁾ and in house mice by ⁽⁶⁾ who noted also that the kidneys covering by highly attachment fibrous layer of connective tissue with abundant amount of perirenal fat tissue. The presence of large amount of fat tissue surrounding both kidneys are act as a good insulator and one of fixatives of kidney in its position.

Shape of kidneys in squirrel appeared semi bean, but in mice the shape was typical bean like structure, and in both animals kidneys smooth surface without any lobulation and fissured, these results was fit to result of ⁽²⁵⁾ in pig kidney shape appeared as bean, the dorsal and ventral surfaces are flat, and the cranial and caudal poles ⁽¹⁸⁾ In jerboa, ^(26;27) dog ,sheep, cattle^(26;27), and camel⁽²⁸⁾, spotted deer⁽²⁹⁾, and musk deer⁽³⁰⁾ which showed that the kidney is firm, reddish - brown in color and disagree with ⁽³¹⁾ who mentioned that the kidney of buffalo was irregular oval in shape, solid in texture; red- brown in color like of ⁽³²⁾ in camel .and disagree but only corresponding in color to the mice (*mus musculus*) but agreed with ⁽⁴⁾ and ⁽⁶⁾, ⁽²¹⁾, rabbit (*oryctologus cuniculus*)⁽³⁰⁾, fat sand rat and jerboa⁽¹⁷⁾ ⁽²⁰⁾, and house mice ⁽⁶⁾ who mentioned normal texture and dark red bodies.

The kidney biometrical measurements are the mean weight of the kidneys in this research the anatomical results were revealed that the kidney of the mice (*mus musculus*) was small relatively, but in squirrel larger than one Anatomical diameter was in male squirrel) mean weight of the kidneys in this research was (1.25±0.03 gm.) a significant differences at $P \leq 0.0.5$ compared with mice. The

mean length, width and thickness of the right kidney were (17.16±0.2 mm, 10.24±0.7 mm, 8.18±0.4 mm) respectively and the mean length, width and thickness of the left kidney were (17.48±0.3 mm, 10.52±0.3 mm, 8.28±0.8 mm) respectively agreement with ⁽³³⁾ in rat who reports the mean weight of kidneys was 0.95gm and the length of right kidney was 1.35 cm and the left was 1.49 cm. similar results of ⁽¹⁸⁾ in jerboa discovered the left kidney was weighted about (1.196±0.35gm) while the right one about (1.175±0.41) gram. This result differed with ⁽⁵⁾ in white rabbit New Zealand who observed that had a mean kidney weight of (0.510±0.012gm). The length of right kidney was ranged about (31.62 ± 0.174) mm, while the length of the left kidney ranged about (30.6 ± 0.159mm). The width of the two kidney were varied, the width of the right kidney are about (20.85 ± 0.155) mm, while the left kidney are about (20.04 ± 0.157) mm. the right thickness about (16.42±0.144) and left one about (17.02±0.13).

But in mice (*mus musculus*) both kidneys lesser than squirrel (*Sciurus anomalus*) with a significant differences at $P \leq 0.05$ was the mean weight kidneys in this research was (0.49±0.02 gm.). The mean length, width and thickness of the right kidney were (10.42±0.9 mm, 6.29±0.6 and 5.74±0.3 mm) respectively and the mean length, width and thickness of the left kidney were (10.30±0.3 mm, 6.36±0.6 mm, 5.73±0.3mm) respectively which corsponding of jebori(2016) who mention The length of right kidney was about (14.62 ± 0.174) mm, while the length of the left kidney ranged about (12.55 ± 0.183) mm, The width of the two kidney were varied, the width of the right kidney are about (5.57 ± 0.349) mm , while the left kidney are about (5.60 ± 0.045) mm. thickness the right thickness about (4.88±0.212) and left one about (5.19±0.201) and unlike the data reported by ⁽⁶⁾ mentioned that the weight of the right kidney was 0.076±0.013gm the left kidney was 0.072±0.011 gm. The mean length, width and thickness of the right

kidneys were .647mm, 5.098±0.427mm, 3.624±0.198 mm respectively those of the left were 6.8±0.518mm, 4.768±0.481 mm, 3.468±0.123 mm respectively Table (2). The study showed the mean thickness of cranial and caudal pole of right squirrel kidney was (7.58±0.9, 6.63±0.2 mm) respectively but in left was (7.81±0.6, 6.79±0.3 mm) respectively and the mean thickness of cranial and caudal pole of right mice kidney was (4.50±0.2, 3.94±0.2mm) respectively but in left kidney of mice was (4.40±0.2, 3.68±0.1 mm) respectively (table 1).

The cortex to medulla index in squirrel (1:2.8) in mice was (1:1.5) Longitudinal section revealed outer most dark brown granulated area referred to cortex. The medulla consists of two distinctive region the outer dark and inner paler medulla with shallow striation.

Conflict of Interest: Nil

Source of Funding: Self

Ethical Clearance: Obtained from Institutional ethical committee

References

1. Yokota, E., Kawashima, T., Oncubo, F., and Sasaki, H. Comparative anatomical study of the kidney position in amniotes using the origin of the renal artery as a landmark. *Okajimas Folia Anatomica Japonica*, 2005;81:135-142.
2. Xiang, G.H. and Wu, A.G. (1997). Dynamic relationship between the water metablism and the concentrations of blood inorganic ions in the two-humped camel (*Camelus bactrianus*). *Chinese Journal of Veterinary Science*.1997; 17:490-494.
3. Cutler, R. E. (2006). Kidney: Biology of the Kidneys and Urinary Tract. In: *The Merck Manual Home Edition*. Retrieved From <http://www.merck.com/mmhe/sec11/ch141/ch141b.html> on 29/12/2020 at 08:00 GMT +3 GMT.2006.

4. Onyeanusi, B. I; Adeniyi, A. A; Ayo, J. O. and Nzalak, J. O. Morphometric studies on the kidneys of the African giant rat (*Cricetomysgambianus* Waterhouse). *Journal of Animal and Veterinary Advances*, 2007;6(11):1273-1276.
5. Al-Jebori, J.G.A., Al-Badri, A.M.S, and Jassim, B.A. Study of the anatomical and histomorphological description of the kidney in adult white rabbits female "New Zealand strain". *Wld J Pharm Pharmaceut Sci*. 2014; 3(6):40-51.
6. Mohamed, A.A. Morphological anatomical and histological study of the normal kidneys in the House Mice (*Mus Musculus*) *MJPS* 2014;;2 (1) pp:83-81.
7. Dhawale, A. and Phatak, R. Visceral gout - a matter of cracking the crystals. *World Poultry*,1998; 14:. 85-87.
8. El-Gohary, Z. M. A. Structural- functional adaptations in the kidneys of two rodent species inhabiting different habitats. *Egypt. J. Zool.*,2009; 52: 337-362.
9. Bozinovic, F; Gallardo, P. A; Visser, R. H. and Corte's, A. Seasonal acclimatization in water flux rate, urine osmolality and kidney water channels in free-living degus:molecular mechanisms, physiological process and ecological implications. *J. Exp. Biol.*, 2003;206: 2959-2966.
10. Janssen CF, Maiello P, Wright MJ Jr, Kracinovsky KB, Newsome JT. Comparison of Atipamezole with Yohimbine for Antagonism of Xylazine in Mice Anesthetized with Ketamine and Xylazine. *Journal of the American Association for Laboratory Animal Science : JAALAS*. 2017 Mar;56(2):142-147.
11. Tammam,O.Y, Taha,A.A; and El-Sherif,M.W. Optimization of Xylazine-Ketamine anesthetic dose in mice suffering chronic liver injury. *Journal of Anesthesia & Critical Care*: 2019; 11:1
12. Al Mamoori,N.(2017). 44 Identification the Gross Structure of the Adult Ox Kidney by Using Corrosion Cast Technique. *Bas.J.Vet.Res.* 15, 145-146
13. Jessica, A.S. and mukilan, R. A Study on Microscopic VascularAnatomy by Luminal Cast Plastination of Renal Blood Vessels Using EpoxyResin in Bulls Kidney *J. Pharm. Sci. and Res.* 2019; 11(6), 2240-2242.
14. Krucker, T, Lang, A & Meyer, EP. New polyurethane-based material for vascular corrosion casting with improved physical and imaging characteristics. *Microsc Res Technol* 2006;69(2), 138-147
15. Verli, F.D, Rossi-Schneider,T.R; Schneider,F.L; Yurgel,L.S AND Lopes de Souza,M.A. Vascular corrosion casting technique steps. *pub med* May-Jun 2007;29(3):128-32
16. El-Gohary, Z. M. A.; Khalifa1, A.; Fahmy, A. M. E. and Tag, Y. M. Comparative Studies on the Renal Structural Aspects of the Mammalian Species Inhabiting Different Habitats. *Journal of American Science*;2011;7(4).
17. Al-Sharoot, H. A. Morphological and histological study of the kidney in giunea pig. *International Journal of Recent Scientific Research* 2014;5(11), 1973-1976.
18. Al-jebori, A. K. H. Histomorphplogical study of kidney in Iraqi jerboa [*Jaculus jaculus*] *Euphrates Journal of Agriculture Science*-2016;8 [3]: 69 – 82
19. Young, Z. J. *The Life of Mammals; their anatomy and Physiology*,1975; second edition, claredom press Oxford,pp: 177
20. El-Salkh, A. B.; Zaki, T.; Mohammad, I. & Khidr, H. A. Anatomical, Histological and Histochemical studies on some organs of true desert rodents in the Egyptian Habitats. *The Egypt. J. Hosp. Med.*2008, 33: 578- 306.
21. Dimitrov, R. Kostov, D. Stamatova K.andYordanova, V.(2012). anatomotopographical and morphological

- analysis of normal kidneys of rabbit (*oryctolagus cuniculus*). Trakia Journal of Sciences, 2012; 10,(2): 79-84
22. Al-Samawy, E. R. M. Morphological and Histological study of the kidneys on the Albino rats. Al-Anbar J. Vet. Sci., 2012; 5 (1)115-116.
23. David, M. A. Kidney transplantation in the rabbit. Lab Invest 2010; 9:385–394.
24. Brewer, N.,Biology of rabbit. Journal of the American Association for Laboratory Animal Science, 2006;45: 8-24,.
25. Kalita, B.; Bora, S.; Sharma, A. K. Plant essential oils as mosquito repellent - a review. Int. J. Res. Dev. Pharm. Life Sci., 2014;3 (1): 741-747
26. Dyce, K. M.; Sack, W. O; Wensing ,C. J. Textbook of Veterinary Anatomy. W.B. Saunders company , Philadephia .PP:428-506. 2010.
27. Dyce, K.M.; Sack, W.O.; Wensing, C. J. Textbook of Veterinary Anatomy .Philadelphia .London.NewYork . 2002.
28. Dowelmadina, I. M. M. Anatomical Characteristics of kidney in one-humped camel (*Camelus dromedarius*) in Sudan. In: The proceedings of the 3rd Conference of the International Society of Camelid Research and Development, 2012;pp 340-342
29. Halder, D.; Roy, M. M.; Mahata, T. K.; Bhattacharjya, M. K.; Hui, A. K. and Dhara, K. C. Histological structure of the kidney of spotted deer (*Cervus axis*). Journal of Interacademia, 2002; 6: 638-641
30. Sudhan , N A ; Suri ,S; Sarma, K; Azmi, S. and Kumar, P. Anatomical study on the kidney of musk deer (*Moschus moschiferus*). Indian Journal of Animal Sciences.2008; 78 (7): 725–726
31. Al-kinanny, A. F. Anatomical, Histological and Radiological study on the kidney and the ureter of Buffaloe “*Bubalus bubalis*” in Middle of Iraq. University of Bagdad. Msc.Thesis. 2006.
32. Khamas, W .H; Ghoshal, N.G; Mohammed, M. Histomorphology of the kidney of one – humpel camel (*Camelus dromedarius*) Iraqi Journal of Veterinary Science . 1993;12(1)
33. Gulnaz, M. ; Tahir, B. ; Munir, D and Sami, M. Protective effects of garlic oil on acetaminophen induced nephrotoxicity in male albino rats. Biomedica, 2010;26, : 9 – 15.