

Original Article

Sexual Dimorphism and Clinical Relevance of Thickness and Angulation of Lateral Lamella of Cribriform Plate-A Multidetector Computed Tomographic Study

Anandagouda V Naikanur¹, Balappa M Bannur², Manjula Patil³, Sanjeev I Kolagi⁴

¹Ph.D Scholar, ²Professor, Department of Anatomy, Shri B M Patil Medical College, Vijayapura. Karnataka, India,

³Associate Professor, ⁴Professor and Head, Department of Anatomy, S Nijalingappa Medical College, Bagalkot, Karnataka, India

Abstract

Background: The aim of this study was to establish the morphometry and sexual dimorphism of lateral lamella of cribriform plate in the North Karnataka region.

Method: Six hundred and forty four (644) Multidetector computed tomographic scans were collected from North Karnataka region and analyzed by using RadiAnt DICOM Viewer. The thickness and angulation of lateral lamella of cribriform plate of olfactory fossa were calculated on both the sides in both genders. Statistical analysis was done by using Student unpaired 't' test.

Conclusion: There was statistically significant difference in the angle of lateral lamella of cribriform plate when compared between right side (mean=106.25°) and left side (mean=109.38°) in males. There was no such difference among females. Statistically significant difference was observed in the angle of lateral lamella of cribriform plate in male patients (mean=106.25°) when compared to female patients (mean=109.61°). The thickness of lateral lamella of cribriform plate was not significant when compared between two sides in males and females. Hence, these variations in the morphometry of the lateral lamella of cribriform plate of ethmoid bone will be of importance for the surgeons in Functional endoscopic sinus surgeries and anterior skull base surgeries.

Key-words: Angle, Ethmoid bone, Lateral lamellae of cribriform plate, Sexual dimorphism, Thickness.

Introduction

The lateral lamella of the cribriform plate (LLCP) is a part of the ethmoid bone in the anterior skull base.

Corresponding Author:

Mr. Anandagouda V Naikanur

Ph.D Scholar, Department of Anatomy,
Shri B M Patil Medical College, Vijayapura
Karnataka- 586103, India. E-mail: goudas.naikanur@gmail.com, drmanjulatil@gmail.com
Phone no: 9986272484.

The LLCP joins laterally with the orbital plate of the frontal bone which protects the olfactory fossa^[1] LLCP forms the lateral boundary of the olfactory fossa. The lateral lamella of the cribriform plate is significantly shorter and less oblique in men than in women. The length of the lateral lamella was greater anteriorly than posteriorly in both sexes.^[2] The two most common sites of skull-base injury associated with endoscopic sinus surgery are the lateral lamella of the cribriform plate and the posterior ethmoid roof near the anterior medial sphenoid wall.^[3] The thin LLCP^[4] offers less resistance to perforation which

can lead to complications like direct penetration, trauma to dura matter, intracranial and intracerebral injuries during surgeries.^[5] Hence, the morphometry of LLCPC provides assesment during various surgical procedures like medial orbital wall decompression.^[6]

Very long and acutely angled lateral lamella predisposes patients to iatrogenic injury during surgeries. The angle of the LLCPC was wider in many diseases like Kallmann syndrome. The angle of LLCPC varies significantly in males and females according to the positions of the skull base.^[7] Type of olfactory fossa with lesser angles are expected to be safer when compared to other types of olfactory fossa with greater angles during surgical procedures.^[8] The level of the ethmoidal roof is affected by the angle of the LLCPC which plays an important role in surgeries of anterior skull base.^[9]

Successful outcome of Endoscopic sinus surgeries with minimal complications can be achieved with prior knowledge of the endoscopic anatomy of anterior skull base and anatomical variations. Hence Radiological investigations and image-guided systems becomes an important tool which help the surgeons to perform safe and successful surgeries.^[10]

With regard to less data available in North Karnataka region, this study was undertaken to determine the morphometry of olfactory fossa in both genders which would help the neurosurgeons and endoscopic surgeons to assess the LLCPC during various skull base and endoscopic sinus surgeries.

Aim

The aim of this study was to establish the morphometry and sexual dimorphism of

Lateral lamellae of cribriform plate in North Karnataka region.

Objectives

- a) To determine the sexual dimorphism of thickness of LLCPC on both sides.
- b) To determine the sexual dimorphism of angle of LLCPC on both sides.

Materials and Method

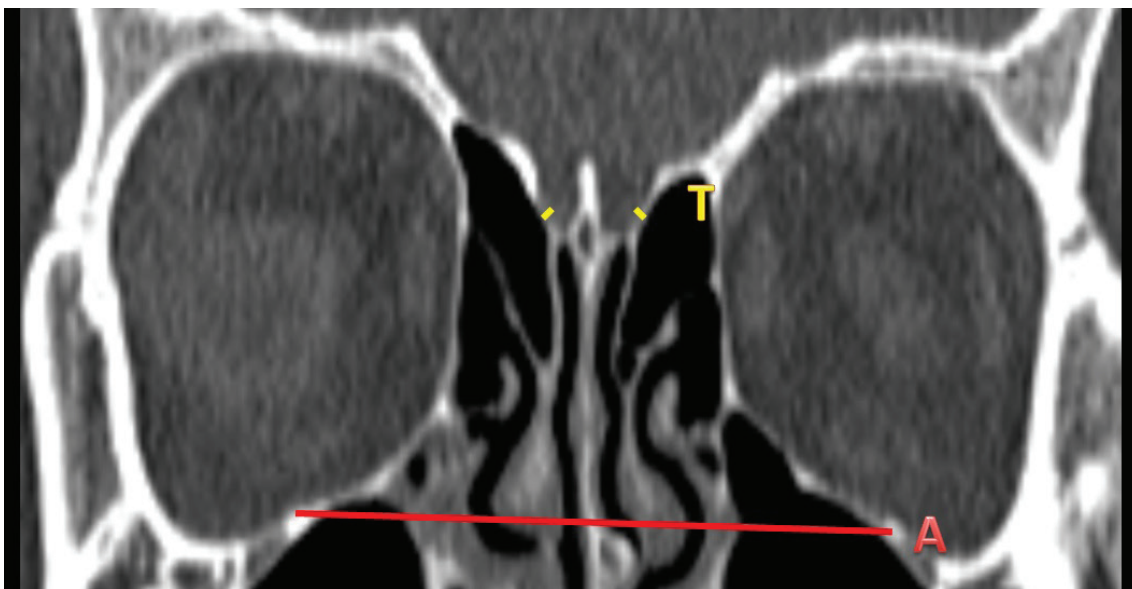Six hundred and forty four Multidetector Computed Tomographic (MDCT) scans of the patients from all the districts of North Karnataka region of Karnataka state, India were collected after institutional ethics committee clearance. This prospective hospital based radiological study was carried out from April 2018 to April 2021.

Normal Paranasal MDCT scans of patients above the age of 16 years belonging to both genders were included in the study.

MDCT scans of Patients below the age of 16 years and MDCT scans of patients with nasal or paranasal trauma, congenital abnormalities of face, tumours or conditions involving bone destruction and surgeries were excluded from the study. While taking the MDCT of paranasal sinuses, patients were informed and instructed about the procedure before obtaining informed written consent. Axial MDCT images of 3mm thickness were taken from CT scanner (Siemens Somatom) by using bone window.

The thickness of LLCPC was measured in both the sides in both genders in direct coronal scan showing the maximum depth of the olfactory fossa at the centre of infraorbital foramen as shown in figure 1.

FIGURE 1: coronal scan showing the thickness of LLCPC at the centre of the infraorbital foramen

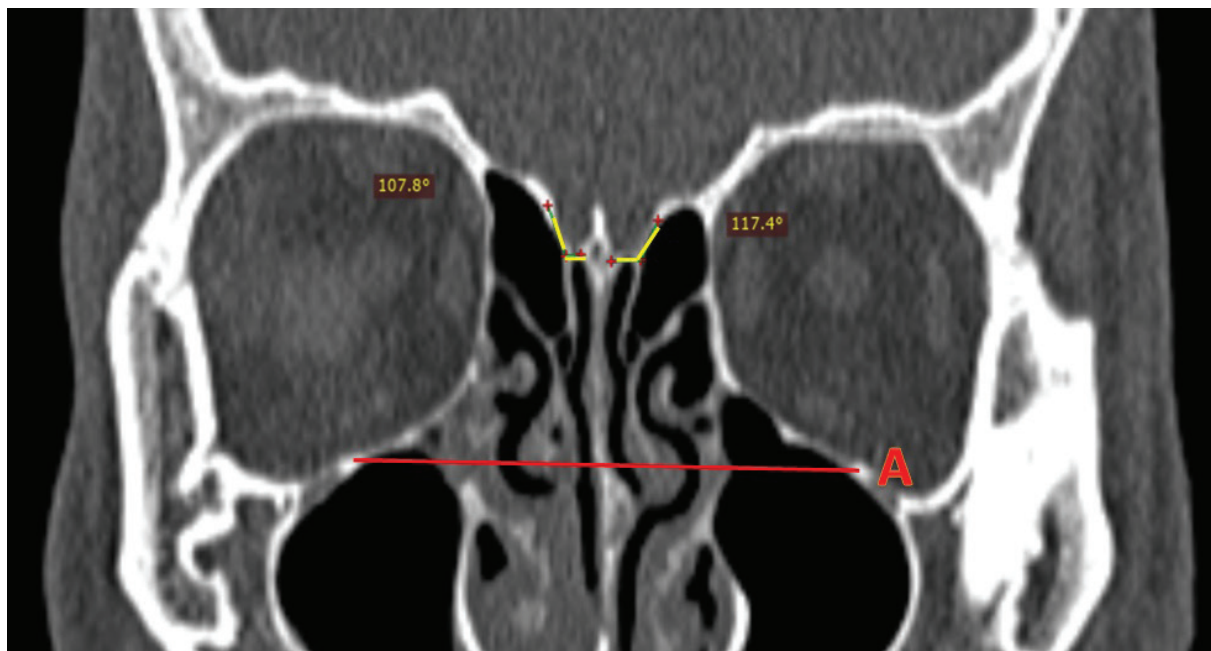


A=line at the level of infraorbital foramen

T=thickness of LLCP

The angle at which LLCP joins the cribriform plate was measured in the direct coronal scan showing the maximum depth of the olfactory fossa at the centre of infraorbital foramen as shown in figure 2.

FIGURE 2: Coronal scan showing the angle of LLCP with cribriform plate at the centre of infraorbital foramen.



A=line at the level of infraorbital foramen

Yellow lines showing the measurement of angle of LLCP with cribriform plate of ethmoid bone on right and left sides.

Comparative calculation of the thickness and angulation of LLCP was done on both the sides in both genders by using RadiAnt DICOM Viewer.

Statistics

Comparison of the thickness and angulation of LLCP on both the sides in both genders will be calculated by using Student ‘t’ (unpaired) test. The data will be considered statistically significant if p is less than 0.05.

Results and Discussion

The present study was carried out to determine the morphometry of the LLCP as there were less data in the North Karnataka region.

Angle of LLCP:

The angle of LLCP on both the sides in males and in females are shown in table 1 and 2 respectively.

TABLE 1: Comparison of thickness and angulation of LLCP in both sides in males in MDCT scans.

Males n*=395	Right side Mean±SD†	Left side Mean±SD†	P‡ value	Significance
Thickness of LLCP	1.26±0.66mm	1.23±0.52mm	0.47	Not significant
Angulation of LLCP	106.25°±20.35°	109.38°±16.81°	0.018	Significant

*(n)=number, †(SD)=standard deviation, ‡(p)=significance value and ||(LLCP)=Lateral lamella of cribriform plate.

Statistically significant difference (p=0.018) was observed in the angle of LLCP between two sides (right side angle=106.25° & left side angle=109.38°) in male patients when compared to female patients.

TABLE 2: Comparison of thickness and angulation of LLCP in both sides in females in MDCT scans.

Females n*=249	Right side Mean±SD†	Left side Mean±SD†	P‡ value	Significance
Thickness of LLCP	1.21±0.56mm	1.22±0.53mm	0.8379	Not significant
Angulation of OF**	109.61°±19.50°	109.99°±18.63°	0.8241	Not significant

*(n)=number, †(SD)=standard deviation, ‡(p)=significance value, ||(LLCP)=Lateral lamella of cribriform plate and ** (OF)=Olfactory fossa.

In females, there was no statistical difference in the angle of LLCP between both the sides as shown in table 2.

Comparison of mean angle of LLCP and its p value of both the sides in both genders are shown in table 3 and 4.

TABLE 3: Comparison of thickness and angulation of LLCP in both sides in both genders in MDCT scans

n*=644		Males (n*=395) Mean±SD†	Females (n*=249) Mean±SD†	P‡value	Significance
Thickness of LLCP	Right Side	1.26±0.66mm	1.21±0.56mm	0.3219	Not significant
	Left Side	1.23±0.52mm	1.22±0.53mm	0.8136	Not significant
Angulation of OF**	Right Side	106.25°±20.35°	109.61°±19.50°	0.03852	Significant
	Left Side	109.38°±16.81°	109.99°±18.63°	0.6674	Not significant

* (n)=number, † (SD)=standard deviation, ‡ (p)=significance value, || (LLCP)=Lateral lamella of cribriform plate and ** (OF)=Olfactory fossa.

Significant difference (p=0.03) in the angle of LLCP was also observed on the right side (mean angle in male patients=106.25° and mean angle in female patients =109.61°) when compared between males and female patients as shown in table 3.

Table 4: Comparison of thickness and angulation of LLCP in both genders in MDCT scans

n*=644	Males (n*=395) Mean±SD†	Females (n*=249) Mean±SD†	P‡ value	Significance
Thickness of LLCP	1.21±0.56mm	1.22±0.53mm	0.8379	Not significant
Angulation of OF**	109.61°±19.50°	109.99°±18.63°	0.8241	Not significant

* (n)=number, † (SD)=standard deviation, ‡ (p)=significance value, || (LLCP)=Lateral lamella of cribriform plate and ** (OF)=Olfactory fossa.

A study done by Luigi maione revealed highly significant wider angles of LLCP in Kallmann syndrome when compared to non congenital hypogonadotropic hypogonadism patients among 37 Kallmann syndrome patients in France.^[11]

Significant differences was observed between lateral lamella angulation in men and women in a

study done by S.Elwany in 300 patients in Egypt.^[2]

Christian Güldner observed that the Patients with Keros type III olfactory fossa having an angle of LLCP with 107° are safer when compared with keros type I and type II olfactory fossa with 116° and 131° respectively on 141 patients.^[8]

The angle of the lateral lamella was $63.1 \pm 17.8^\circ$ anteriorly and $39.1 \pm 17.9^\circ$ posteriorly ($p < 0.05$) in a study done by Lucas Kus.^[7]

Tony Jacob observed that there was no significant difference in the angulation of the LLCP on left and right sides ($p > 0.05$).^[12]

Thickness of LLCP:

The thickness of LLCP on both the sides in males and in females are shown in table 1 and 2 respectively. Comparison of mean thickness of LLCP and its p value of both the sides in both genders are shown in table 3 and 4. There were no significant differences observed in the thickness of LLCP between both the sides and in between the genders.

Keast A has revealed that the thickness of LLCP can vary from 0.2 to 0.05 mm.^[13]

STRENGTHS AND LIMITATIONS OF THE STUDY:

This study will help neurosurgeons and endoscopic surgeons to assess LLCP during various skull base and endoscopic sinus surgeries as there were less data in North Karnataka region.

Only adult patients were included in the present study. This study was carried out only in patients of North Karnataka region during the study period.

Conclusion

The thin LLCP offers less resistance to perforation which can lead to complications during various surgical procedures. Statistically significant difference ($p=0.018$) was observed in the angle of LLCP between two sides (angle= 106.25° on right side & angle= 109.38° on left side) in male patients. In females, there was no such difference. Significant difference ($p=0.03$) in the angle of LLCP was also observed on the right side (angle= 106.25° in male patients and angle= 109.61° in female patients) when compared between males and female patients.

The thickness of LLCP was not significant when compared between two sides in males and females. Hence, the morphometry of LLCP provides assessment in skull base surgeries.

Ethical Clearance: Ethical clearance was taken from BLDE (deemed to be university) Shri B M patil Medical college, hospital and research centre, Vijayapura, Institutional ethical committee and SNMC –Institutional ethics committee on human subjects research, Bagalkot.

Source of Funding – Self

Conflict of Interest – Nil

References

- [1] Standring S. Grays Anatomy, The anatomical basis of clinical practice, 40th ed. Churchill Living stone, London (UK); 2008.472.
- [2] Elwany S, Medanni A, Eid M, Aly A, El-daly A, Ammar SR. Radiological observations on the olfactory fossa and ethmoid roof. The Journal of Laryngology & Otology 2010;124:1251-6.
- [3] Schlosser RJ, Bolger WE. Nasal Cerebrospinal Fluid Leaks: Critical Review and Surgical Considerations. Laryngoscope 2004 Feb;114(2):255-65.
- [4] Bista M, Maharjan M, Kafle P and Shreshta S. Computed tomographic assessment of lateral lamella of cribriform plate and comparison of depth of olfactory fossa. J Nepal Med Assoc 2010;49(178):92-5.
- [5] Kumar VN, Gugapriya TS, Arun T et al. A Computerized tomographic study of height of ethmoidal skull base. Int J Clin Trials 2014;1(2):37-40.
- [6] Gauba V, Saleh GM, Dua G, Agarwal S, Ell S & Vize C. Radiological Classification of Anterior Skull Base Anatomy Prior to Performing Medial Orbital Wall Decompression. Orbit 2006;25(2):93-96.
- [7] Kus L, Monteiro E, Almeida JD, Lee J, Vescan

- A. The Radiological Anatomy of the Olfactory Fossa. *J Neurol Surg* 2015;76–90.
- [8] Guldner C, Diogo I, Windfuhr J, Bien S, Teymoortash A, Werner JA & Bremke M. Analysis of the fossa olfactoria using cone beam tomography (CBT). *Acta Oto-Laryngologica* 2011;131(1):72–78
- [9] Nair S, Ibrahim A. The Importance of Cribriform-Lamella Angle in Endoscopic Sinus Surgery. *Indian J Otolaryngol Head Neck Surg* 2020;73(1):66-71.
- [10] Gupta AK, Bansal S, Sahini D. Anatomy and Its Variations for Endoscopic Sinus Surgery. *Int J Clin Rhinol* 2012;5(2):55-62.
- [11] Maione L, Benadjaoud S, Eloit C, Sinisi AA, Colao A, and Chanson P et al., Computed tomography of the anterior skull base in Kallmann syndrome reveals specific ethmoid bone abnormalities associated with olfactory bulb defects. *J Clin Endocrinol Metab* 2013;98(3):537-46.
- [12] Jacob TG, Kaul JM. Morphology of the olfactory fossa, A new look. *J Anat Soc India* 2014; 63:30-5.
- [13] Keast A, Sofie Y, Dawes P and Lyons B. Anatomical variations of the paranasal sinuses in Polynesian and New Zealand European computerized tomography scans. *Otolaryngol-Head Neck Surg* 2008;139(2):216–21.