

The Effect of Zinc and Nano Zinc Supplementation on Serum Testosterone and Testicular Histology in Male Rats

Adil A. Mustafa¹, Khalaf N Ahmed¹, Tamathir A Hamoudi², Azzawi M Hadi³

¹Lecturer College of Agriculture - Tikrit University - Department of Food Sciences, ²Lecturer, College of medicine, Ninevah University, Department of Chemistry and Biochemistry, ³Prof., College of Medicine, Ninevah University, Department of Surgery

Abstract

Background : Infertility is a universal medical problem, 50% was contributed to male factors. Zinc is an important elements for all living cells and it is one of the most important trace elements in our bodies. Nanoparticles, are mall particles, that have a large surface area if compared to their size, this small size, help them to enter into living cells easily. This makes them an essential participant in all biological interactions and their modern applications. The aim was to evaluate the effects of Zinc and Nano zinc on male gonads histology and function. **Methods:** A double blind case control study, designed to test the effects of Zinc oxide and Nano zinc oxide on 20 rats that were divided randomly into 4 equal groups. Control, Zinc, Nano zinc, and hybrid (zinc and Nano zinc) group. The dose was 0.11mg/kg. **Results:** There was significant change in in serum Zinc and testosterone, more in ZnNPs containing groups. While the histological picture of testis ameliorated in zinc arm, but worsen in ZnNPs arm of experiment. These results lead to the **Conclusion** that Nano zinc though improve S. testosterone, it can damage the testicular tissues in certain doses.

Key words: Zinc, Nano-zinc, sex hormones, testosterone, infertility.

Introduction

There was a variable rates of infertility among nations, and regions. It was estimated that around 15% of partners are infertile and that half of their infertility is caused by male related factors¹. Zinc is one of the important elements present in all living things and it is one of the most important trace elements in our bodies. It is important for the growth and development of living cells, so that it presents in all body tissues and secretions in relatively high concentrations, especially in the prostate tissues and secretions. The average amount of zinc present in the body is about (1.4-2.3 gm.)^{2,3,4,5}. Many body systems were impacted by zinc like the reproductive, nervous, immunity, skin, and GIT systems¹.

Androgen production in our bodies is found to depend on zinc levels. The spermatozoa utilize zinc from seminal fluid after ejaculation (mainly prostatic), so the spermatozoal zinc will get higher after sperms exposed to prostatic part of seminal fluid, and this will enhance

sperms' maturation⁶.

Nanoparticles, are defined as small particles with a dimension in the range (1-100 Nanometers), they have a large surface area in comparism to their size, different degrees of biological effects, chemical reactions, and highly distinctive characteristics appear collectively in other materials. Because of their small size, they can be easily entered into living cells, which makes them an essential participant in all biological interactions and their modern applications⁷. Due to their distinct characteristics, they are increasingly used in various applications such as the pharmaceutical industry and bioengineering. They are also used in biomedical applications such as the manufacture of anti-cancer drugs and as antibacterial, and antifungal materials⁸, although ZnO is used as a vector for drug delivery, it still has cytotoxicity⁹. The study aimed to evaluate the effects of Zinc and Nano zinc on male gonads histology and function.

Materials and Methods

A double blind case control study, designed to test the effects of Zinc oxide and Nano zinc oxide on rats. A twenty mature male rats were divided randomly into 4 groups. Each group included 5 animals which included, Control group, Zinc group (Zn 0.11 mg / gm , Nano zinc (ZnNPs) 0.11 mg / gm and a hybrid group of both zinc and Nano zinc (Zn + ZnNPs) (0.055 mg / gm) for each of them. After 4 weeks of oral feeding, the biochemical and histological studies done.

Statistical analysis: The data were analyzed statistically through the experiments system within the ready statistical program (SAS, 2012), and by using the complete random design system (CRD), as the averages were chosen according to Duncan’s test¹⁰.

Results

Table (1) shows the effect of zinc (Zn) and Nano-zinc (ZnNPs), and mixture of both (zinc and Nano-zinc)

on the concentration of albumin, Zinc, and testosterone in serum. It showed a significant increase in the amount of albumin with oral administered Zn, it reached (4.38) While it was not significantly affected by the oral administration of ZnNPs and the mixture of Zn + ZnNPs (3.88, 3.94) respectively, as compared to the control group that average estimated level was (3.98). The results also showed that serum zinc had a non significance increment with the oral administration of Zn (119.6) as compared with control group (117.8). While the nano group arms of the study show significant increase of of serum zinc as compared with the control group , while zinc absorption was significantly increased when the oral administration of ZnNPs and the mixed Zn + ZnNPs reached (133.4,160.4), respectively. It was shown that the oral administration of Zn, ZnNPs and Zn + ZnNPs increase the level of testosterone to a significant levels . As it reached (5.17,5.60,6.10), respectively, compared with the control group, where it was (4.53).

Table (1): concentration of the serum albumen, Zinc, and testosterone in control and study groups of white male rats.

	Control	Zn	ZnNPs	Zn+ ZnNPs
S. Albumin (g/dl)	3.98 b	4.38a*	3.88b	3.94b
S. Zinc (µg/dl)	117.8c	119.6c	133.4b*	160.4a*
S. Testosterone(ng/dl)	4.53b	5.17ab	5.60a*	6.10a*

**differed lowercase letters in one row mean that there is significant difference between study and control groups at 0.05 probability level.*

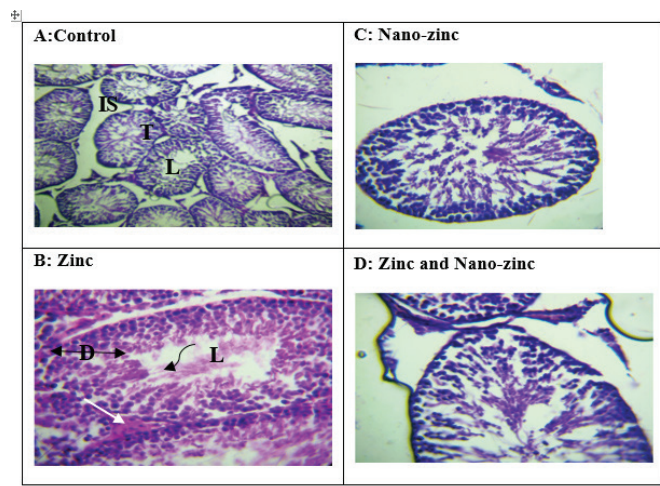


Figure 1: The Histology of the testes in control and study groups.

T: seminiferous convoluted tubules; **D:** the stages of developmental spermatogenesis(**black arrow**) within the Lumen of the tubules (**L**), the spermatids (**curved arrow**) in the lumen of each tubule. Lydger cells(**white arrow**) found in the intertubular space (**IS**).

The testis histology of control group showed that testicular tissue contained large numbers of seminiferous coiled tubules and each tubule contained the different stages of developmental spermatogenesis, starting with spermatogonia cells based on the basement membrane, then primary spermatocyte, then two rows of secondary spermatocyte, which in turn They are transformed into smaller spermatocytes close to the center of the lumen of each tube (the spermatids), and those spermatids are transformed into sperm at the lumen of the seminiferous tubules.

The picture (B) represent the testis of Zinc group, each convoluted tubule contains an abundance of spermatogonia stabilized on the basement membrane with dark nuclei, then another row of primary spermatocytes and more than two rows of secondary spermatocytes that transformed into several rows of spermatids close to the center of the lumen of the convoluted tubule. Bundles of sperms with a curdled liquid were noticed in the center of the lumen. This fluid is homogeneous, red in color. It has also been observed Lydger cells among the tubules which have endocrine function of testosterone secretion.

The picture (C) represent the testis of Nano-Zinc group, demonstrated the convoluted seminiferous tubule, in which the spermatogenic precursors had enlarged nucleus for those cells that compact with each other, these enlarged nuclei gives the compact cells in the section the dark view. The primary and secondary spermatocytes were found in the form of compact clumps also dark, while the spermatogenic precursors appeared in the form of separate groups at the edge of the lumen and within it. , The sperms were not noticed in the lumen where it supposed to be appeared. There was mass degeneration for some sperms in the lumen.

The picture (D) represent the testis of Zinc and Nano-Zinc group, it shows that the convoluted tubules contained a thickening of the basement membrane surrounding each tubule with the degeneration of sperm cells in various developmental stages. The center of the

tubules show a presence of small clumps of cells, while the sperms were not clearly observed in the lumen, but rather a degenerated clumps near the edge.

Discussion

Medicines fixed on nanoparticle evolved to raise efficacy of drugs by, safeguard from digesting enzymes of the GIT and consequently improve absorption and bioavailability via oral dosage, as well it extends the drugs half-life in the serum. Due to its small size it can bypass the blood and tissue specific barriers, and enhance carriage of drugs to their specified tissues, or cells. It hastens the onset and extends the therapeutic effects; as well it reduce the needed therapeutic dose and hence reduces the unwanted effects and lessens the risk of toxicity¹¹. Nano particles enhance absorption of Zn, hence enhance bioavailability in both serum and cells, the cytotoxicity also increased due to this increment¹². These facts could explain the higher level of serum Zinc in Nano arm of the study, and it can be proposed that the testicular Zinc in Nano arm (at that dose) was reached the toxic level that lead to a severe tissue damage as shown in picture C and D. unfortunately the tissue levels of Zinc in the testicular tissue hadn't measured.

Many studies that investigate Nano Zinc toxicity used a large doses in their experiment both in vitro and in vivo studies. Nanoscale zinc oxide proved to have both oxidative(which was concentration dependent)¹³ and antioxidant effects(as it had been found to be associated with reduction of glutathione in rats)¹. Low doses of Zinc has favorable effect on metallozymes, transcription factors, immune precept and cell growth and proteins synthesis. It also plays antioxidant, anti-apoptotic and anti-inflammatory act. Nano zinc in higher dose, conveys a toxic effects via oxidative stress activity which is time and concentration related. The zinc oxide nanoparticles in high doses can made the individual prone to thrombosis, It can pass through blood-testis barriers easily. It had been shown that the higher the dose and the longer the time exposure , the more the damage¹³.

The toxic effect of Nanoscale Zn causes the seminiferous tubules to be segregated, with random arrangement of developing germ cell layers, with a low sperm count in the lumen of the tubules. These toxic effects was more prominent in higher doses. There was

a degeneration of the seminiferous tubules with wider spaces in between, the Sertoli and Leydig cells shows a prominent vacuolization. These changes increased with increased dose of treatment as severe as absence the seminiferous tubules, and spermatogenic cells count in all stages was decreased, due to degeneration and necrosis. There is evidence of cell shedding and edema of intertubular space¹⁴.

Zinc could modulate the sperm function by many different mechanisms. One of them is the action of zinc as a cofactor for several hundred metalloenzymes, particularly the enzymes responsible for protein synthesis¹⁵, and that's why the serum albumen increased in all arms of the study as compared with the control.

One experiments showed that giving ZnNPs to animals lab with induced diabetes for a month lead to a significant elevation of their level of testosterone if they compared with the untreated group with diabetes, which returned to normal levels after treatment¹⁶. Zinc potentiate the release of LH and FSH from the pituitary, this promote production of testosterone as well suppress the enzyme known as aromatase which catalyze conversion of testosterone into estrogen. These two effects of Zn promotes the sexual and reproductive capability of individual on Zn treatment.¹⁷

Conclusion

Although there is significant increase in serum testosterone, the histology of testis with Nano zinc arm of the study shows non favorable changes of seminiferous tubules represented by degeneration of spermatids and sperms, if compared with control or Zinc alone group.

Ethical Clearance: None

Source of Funding: None

Conflict of Interest: None

References

- Mossa MM, Azzawi MH, Dekhel HH. Role of zinc in management of male infertility. *Tikrit Medical Journal*. 2011;17(1), 2727-3 https://www.researchgate.net/publication/324831754_Role_of_zinc_in_management_of_male_infertility
- Stefanidou M, Maravelias C, Dona A, and Spiliopoulou C. Zinc: a multipurpose trace element. *Archives of toxicology*. 2006; 80 (1), 1-10. <https://doi.org/10.1007/s00204-005-0009-5>
- Calesnick B, Dinan AM. Zinc deficiency and zinc toxicity. *Am Fam Physician*. 1988 Apr;37(4):267-70. PMID: 3358349.
- Prasad AS. Zinc: role in immunity, oxidative stress and chronic inflammation. *Curr Opin Clin Nutr Metab Care*. 2009 Nov;12(6):646-52. doi: 10.1097/MCO.0b013e3283312956. PMID: 19710611.
- Bhowmik, D., Chiranjib, K. P., and Kumar, S. A potential medicinal importance of zinc in human health and chronic disease. *Int J Pharm*. 2010;1(1);5-11. https://www.researchgate.net/publication/277014212_A_potential_medicinal_importance_of_zinc_in_human_health_and_chronic_disease
- Mossa MM, Azzawi MH and Dekhel HH. Effect of Selenium in Treatment of Male Infertility. *Experimental Techniques in Urology & Nephrology*. 2018; 1(5), 1-4. 10.31031/ETUN.2018.01.000521
- Mohammadi FF, Noori A, Momayez M, Sadeghi L, Shirani K, and Yousefi BVB The effects of nano titanium dioxide (TiO₂) in spermatogenesis in wistar rat. *Euro J Exp BIO*. 2013; 3 (4), 145-9. www.pelagiaresearchlibrary.com
- HASSANI S M, NAKHAEI M M, and Forghanifard M M. Inhibitory effect of zinc oxide nanoparticles on pseudomonas aeruginosa biofilm formation. *Nanomed J*, 2015; 2(2):121 -128. 10.7508/NMJ.2015.02.004
- Ma H, Williams PL, Diamond SA. Ecotoxicity of manufactured ZnO nanoparticles--a review. *Environ Pollut*. 2013 Jan;172:76-85. doi: 10.1016/j.envpol.2012.08.011. Epub 2012 Sep 17. PMID: 22995930.
- Duncan D. Multiple range and Multiple F-Test. *Biometrics*. 1955;11(1), 1-42. <https://doi.org/10.2307/3001478>
- Laura F, Wael AK, Mahmoud H, Waleed FA. Perspectives of nanotechnology in male fertility and sperm function. *International Journal of Veterinary Science and Medicine*. 2018; 6, 265–9. <https://doi.org/10.1016/j.ijvsm.2018.09.001>
- Gheetha K, Chellapandian M, Arulanathan N, Ramanathan A. Nano zinc oxide – An alternative zinc supplement for livestock. *Veterinary world*. 2020; 13(1), 121-126. <https://doi.org/10.1016/j.aninu.2016.06.003>

13. Espanani HR, Faghfoori Z, Izadpanah M, Babadi VY. Toxic effect of nano-zinc oxide. *Bratisl Lek Listy*. 2015;116(10):616-20. doi:10.4149/bll_2015_119. PMID: 26531873.
14. Tang Y, Chen B, Hong W, Chen L, Yao L, Zhao Y, Aguilar ZP, Xu H. ZnO Nanoparticles Induced Male Reproductive Toxicity Based on the Effects on the Endoplasmic Reticulum Stress Signaling Pathway. *Int J Nanomedicine*. 2019 Dec 4;14:9563-9576. doi: 10.2147/IJN.S223318. PMID: 31824151; PMCID: PMC6900315.
15. Muhlrad PJ, Clark JN, Nasri U, Sullivan NG, LaMunyon CW. SPE-8, a protein-tyrosine kinase, localizes to the spermatid cell membrane through interaction with other members of the SPE-8 group spermatid activation signaling pathway in *C. elegans*. *BMC Genet*. 2014 Jul 14;15:83. doi: 10.1186/1471-2156-15-83. PMID: 25022984; PMCID: PMC4105102.
16. Afifi M, Almaghrabi OA, Kadasa NM. Ameliorative Effect of Zinc Oxide Nanoparticles on Antioxidants and Sperm Characteristics in Streptozotocin-Induced Diabetic Rat Testes. *Biomed Res Int*. 2015;2015:153573. doi: 10.1155/2015/153573. Epub 2015 Oct 25. PMID: 26581756; PMCID: PMC4637006.
17. Al-Ani NK, Al-Kawaz U, and Saeed BT. Protective influence of zinc on reproductive parameters in male rat treated with cadmium. *American Journal of Medicine and Medical Science*. 2015; 5(2), 73–81. doi:10.5923/j.ajmms.20150502.03